

MEDICAL HISTORY  
OF THE  
WAR OF THE REBELLION.

---

WATER COLOR DRAWINGS  
TO ILLUSTRATE  
FLUXES AND FEVERS.

---

U.S.  
SURGEON GENERAL'S OFFICE.


SURGEON GENERAL'S OFFICE

**LIBRARY.**

Section

*Bottom Cox #54*

No. *133543*





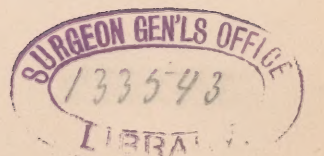
U.S. Surgeons general's office

ORIGINALS of the CHROMOS

IN THE

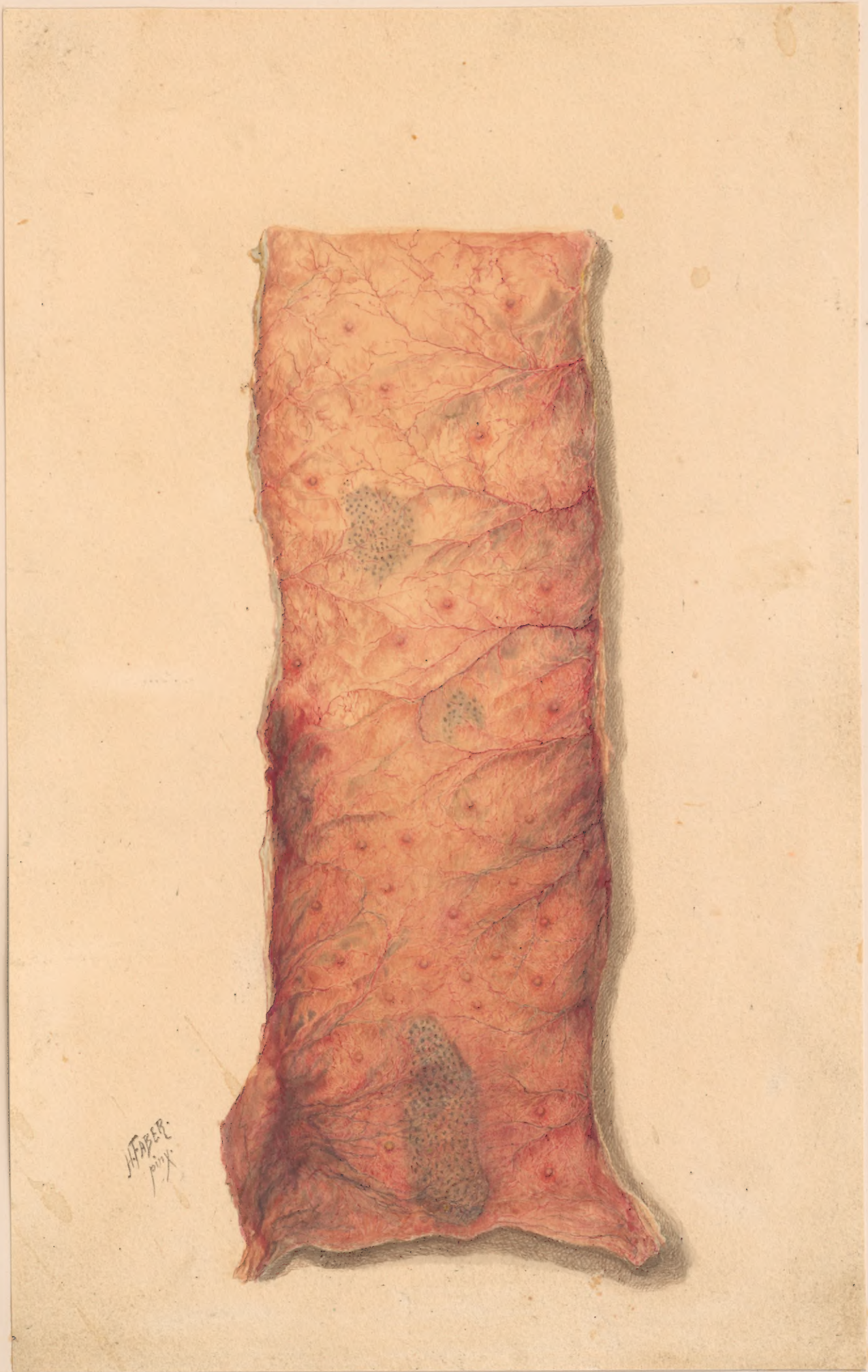Second Vol. Medical History.

Vol. I Pt. 2



Art coll.  
UH  
224  
1861/65  
fA31

NLM

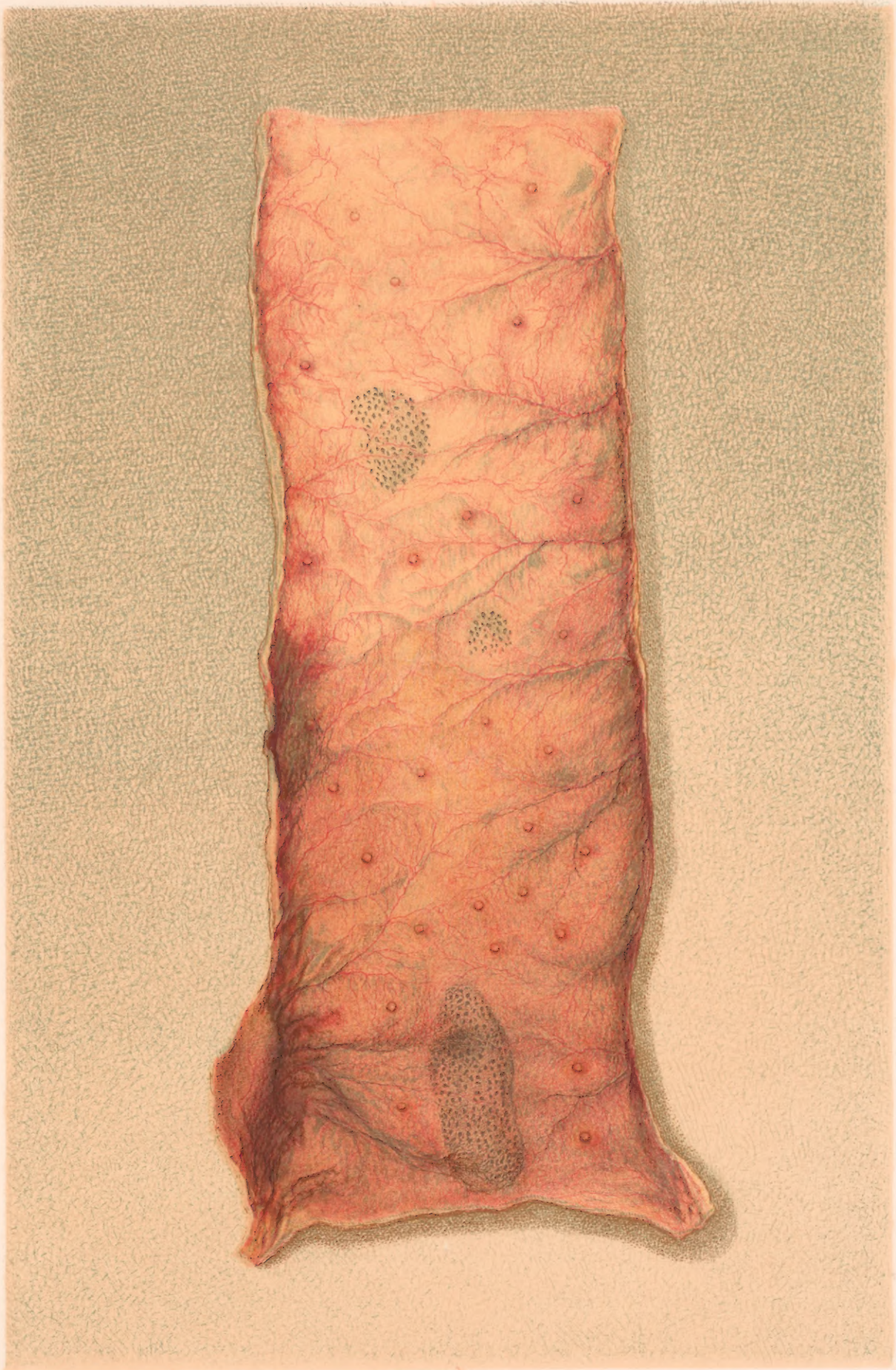

HABER  
1892





102

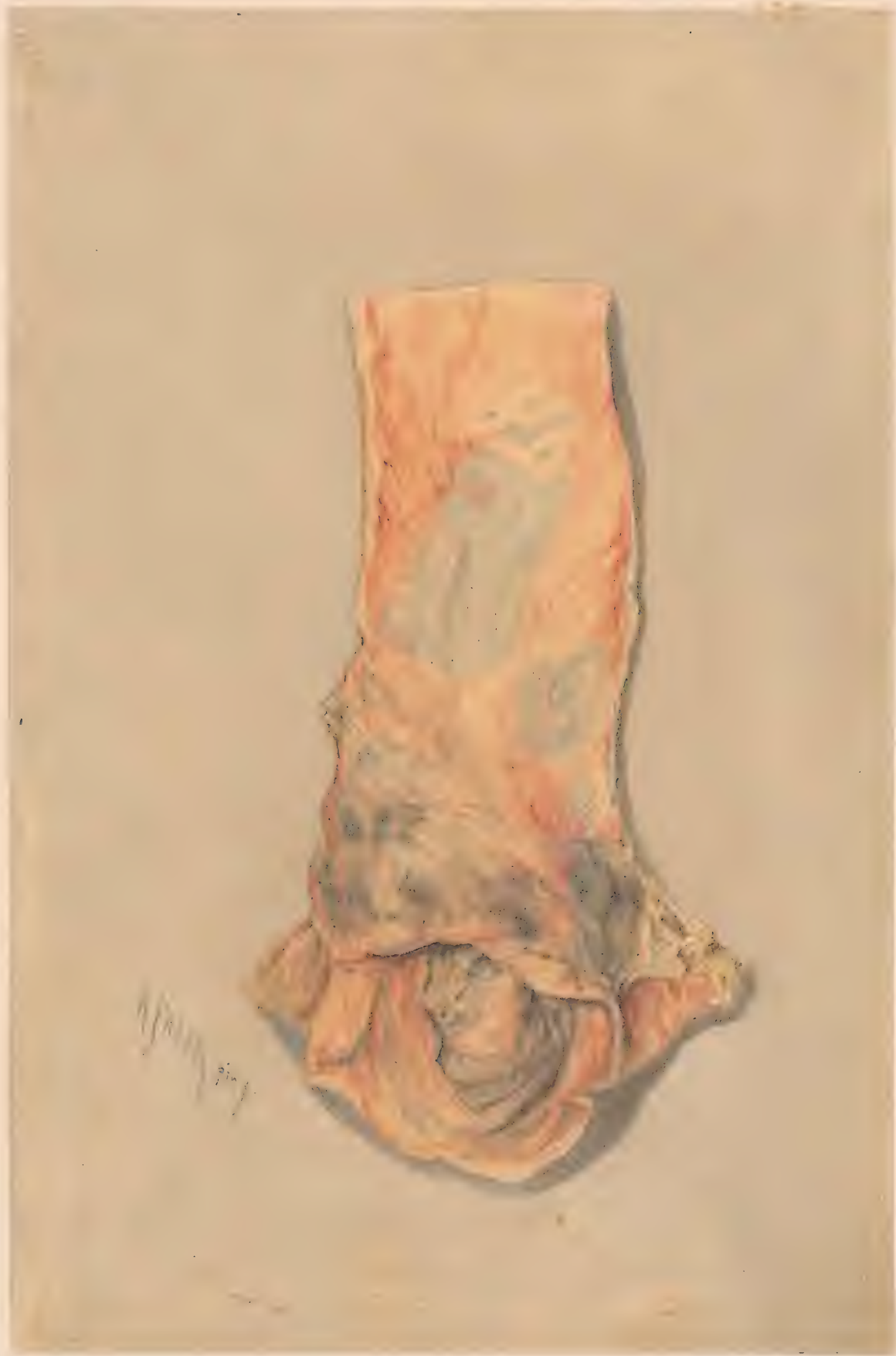

H. Faber pinx.

F. Moras chromolith. Phil.

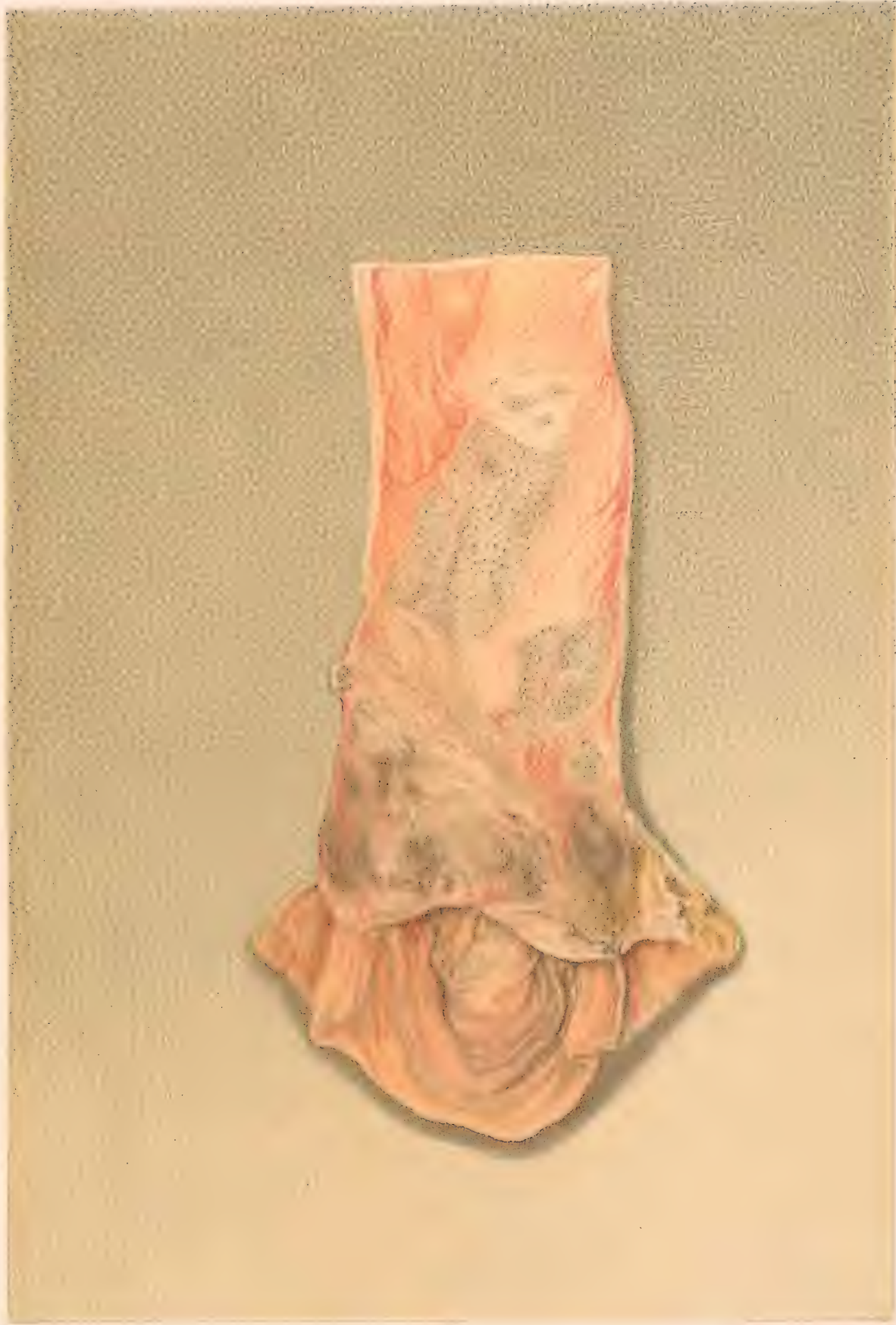PORTION OF ILEUM WITH INFLAMED MUCOUS MEMBRANE,  
solitary follicles enlarged, and shaven-beard appearance of Peyer's patches.





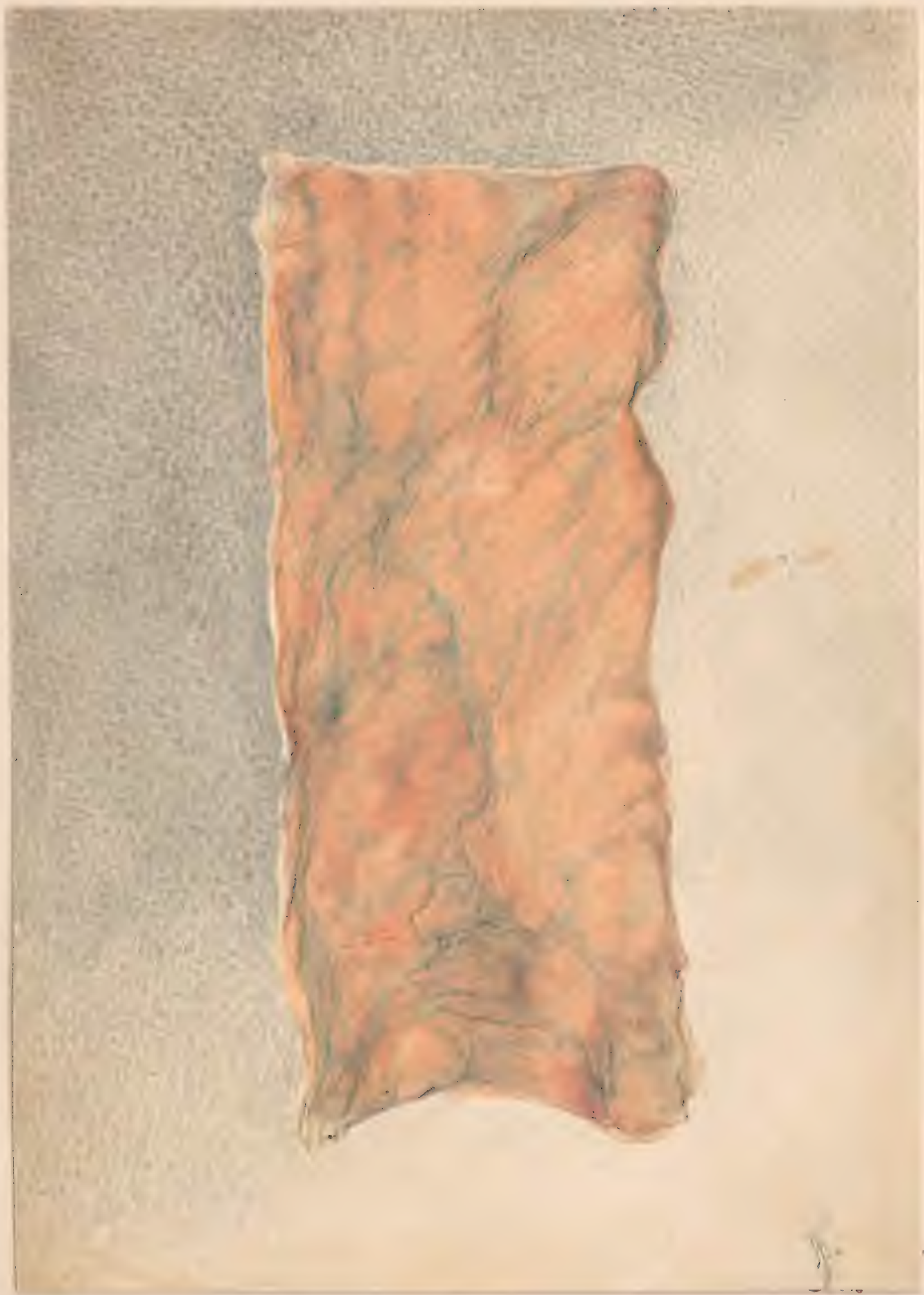

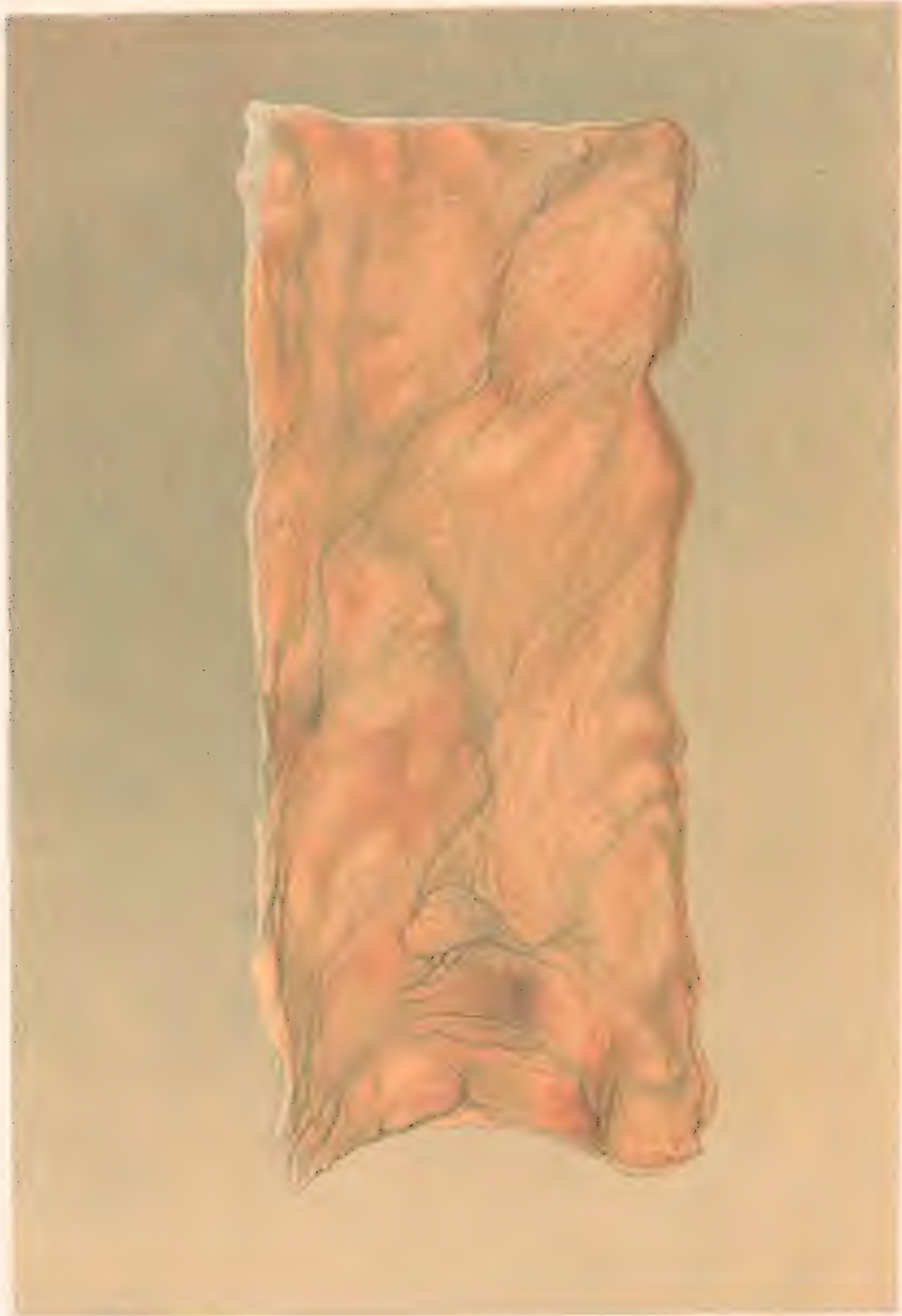
20



PIGMENT DEPOSITS IN MUCOSA  
near the ileo-cæcal valve. Shaven-beard appearance.







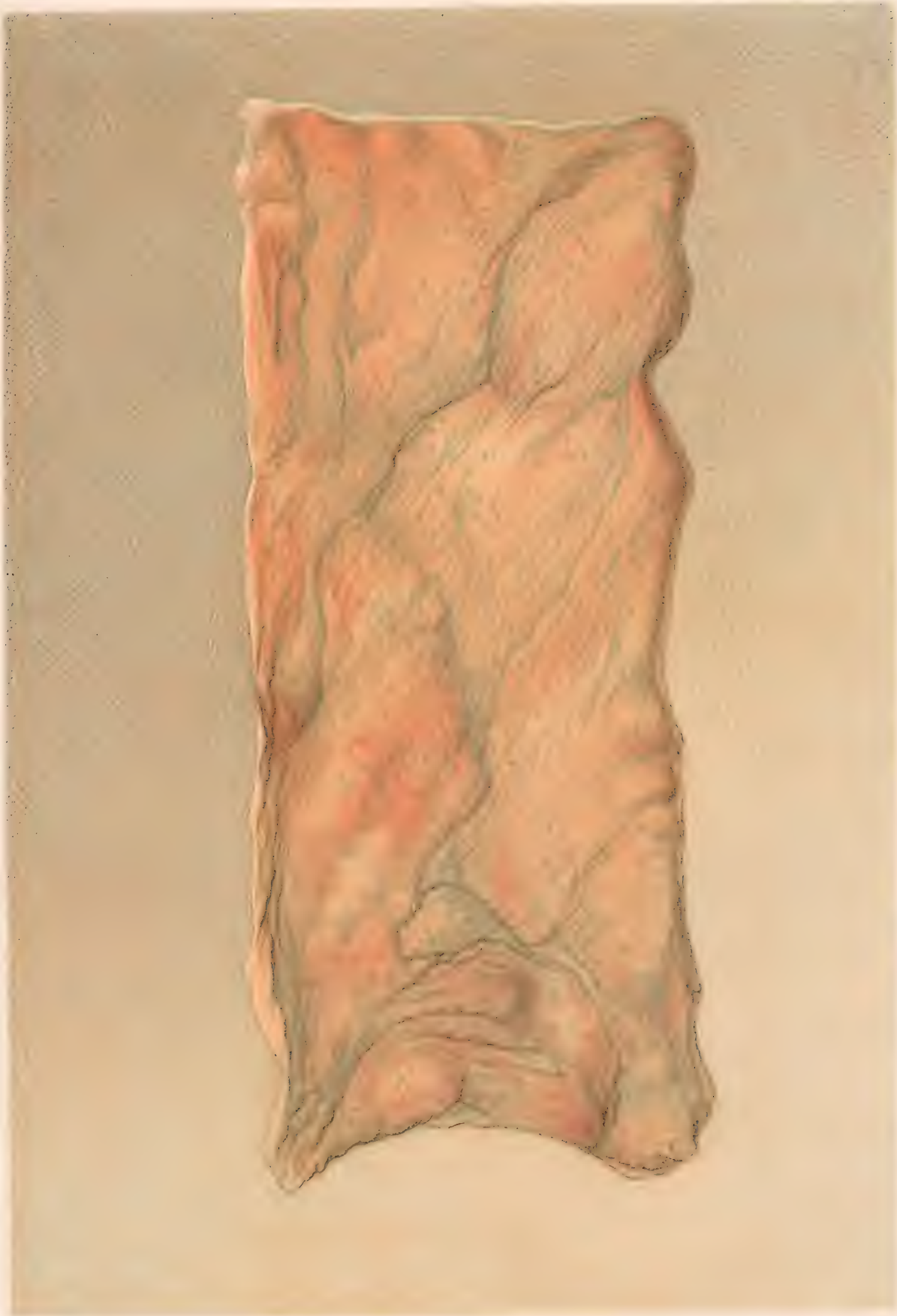
H. Faber pinx.

F. Meunier sculp. 1861

COLON WITH PIGMENT DEPOSITS

In and around the solitary Glands. - Dysentery





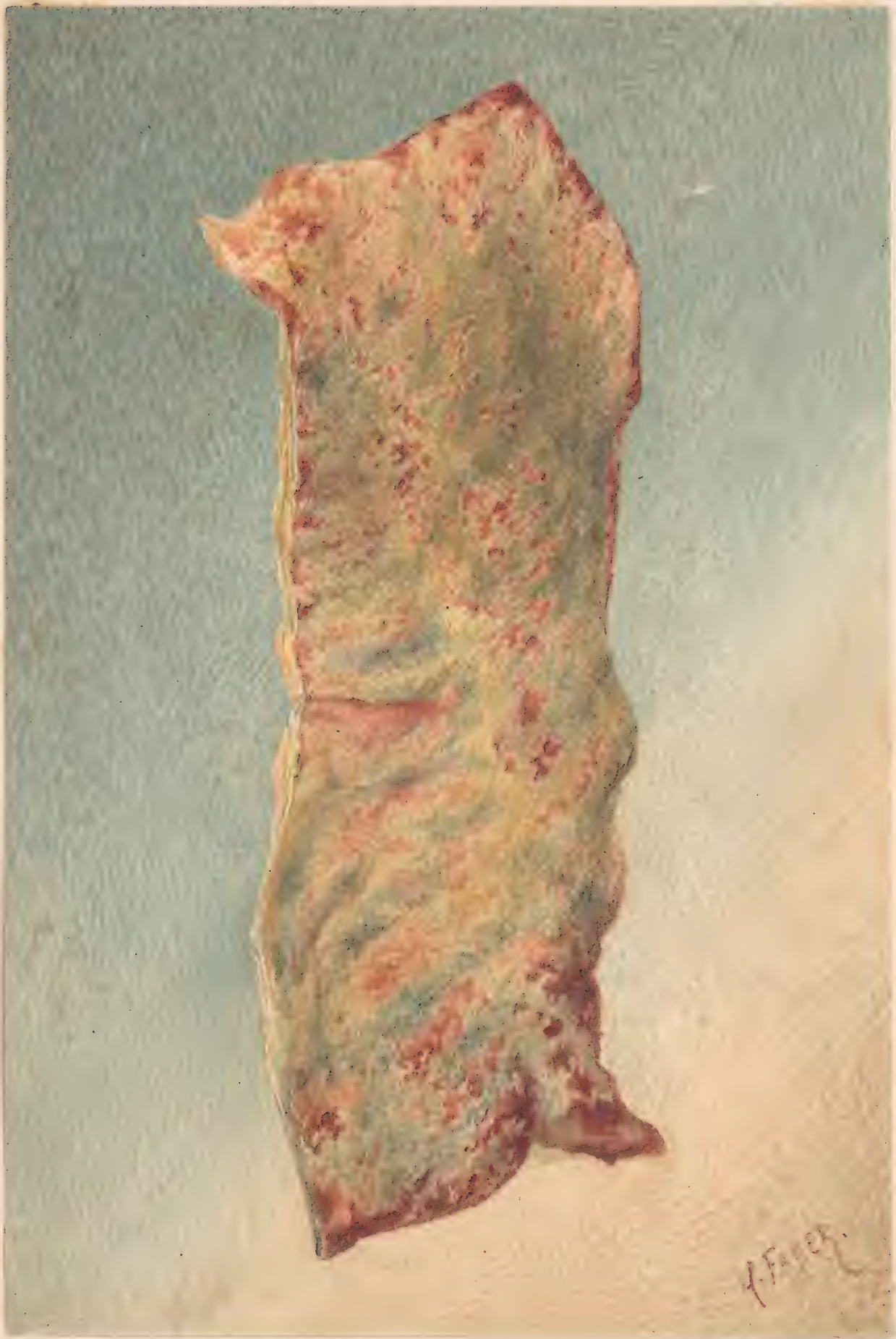H. Faber pinx.

F. Merce lith. Philad.

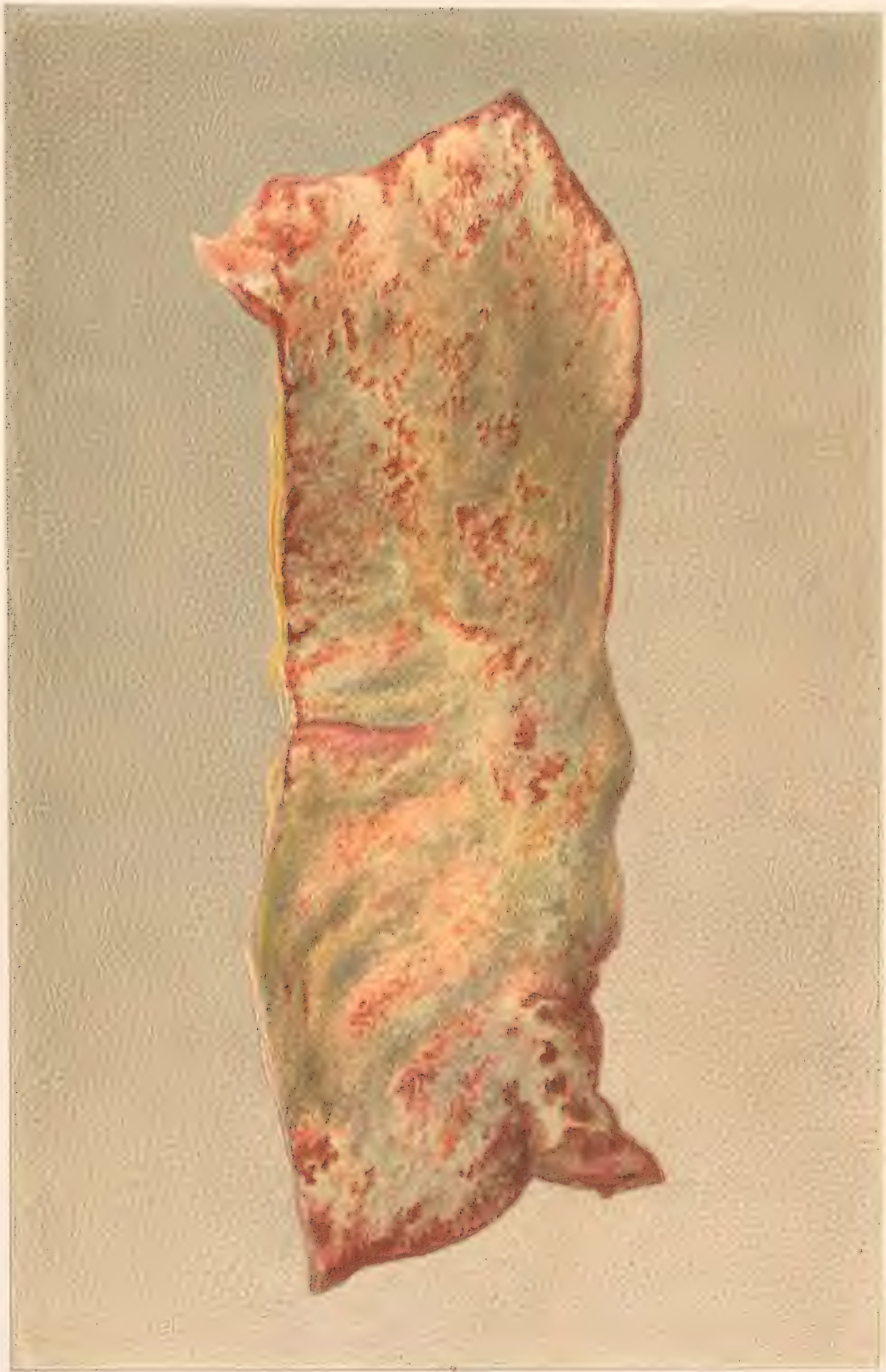**COLON WITH PIGMENT DEPOSITS**

In and around the solitary Glands









F. Moras chromolith Phyl<sup>14</sup>

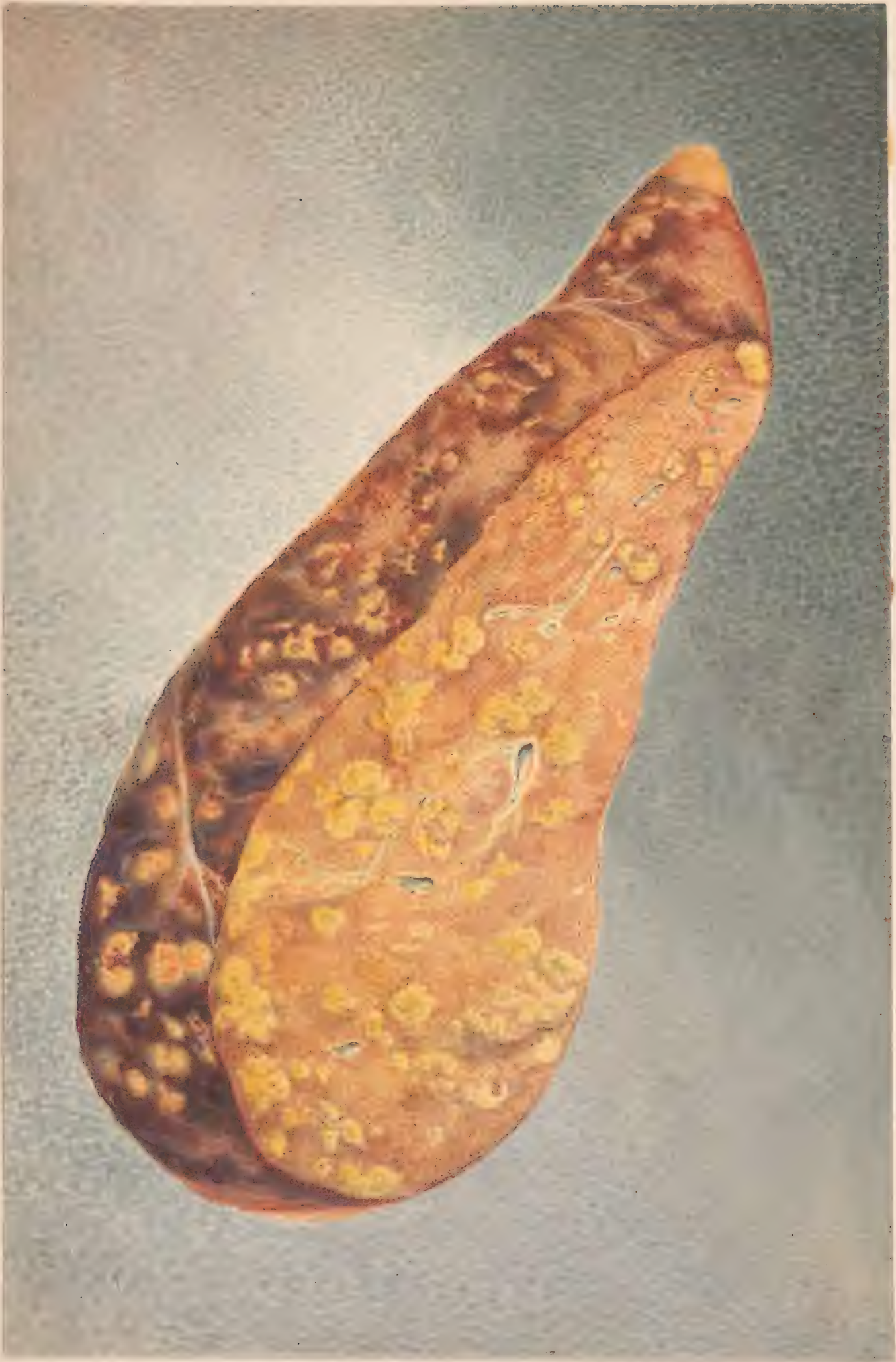PORTION OF DESCENDING COLON,  
covered with pseudo-membrane.











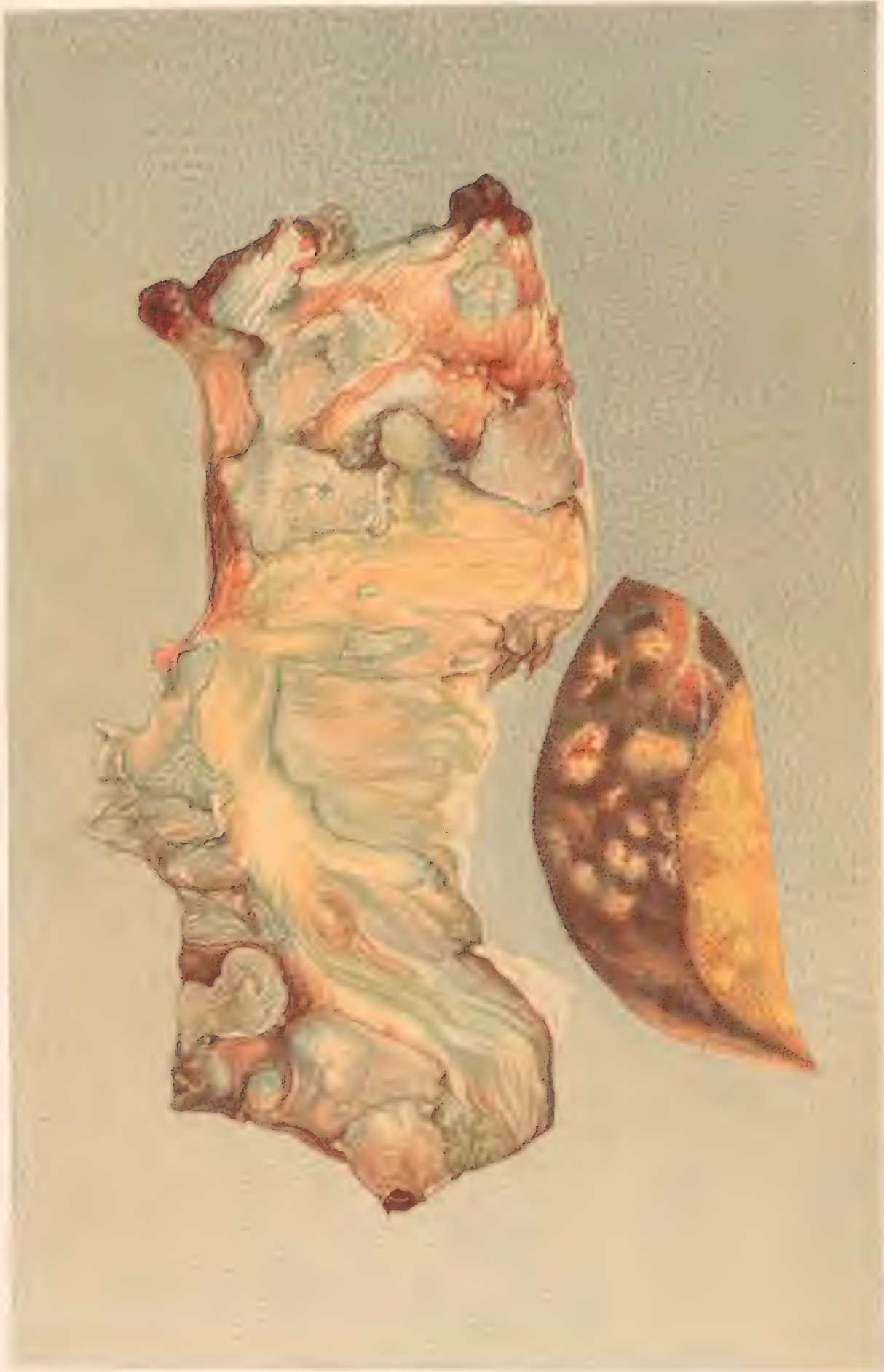
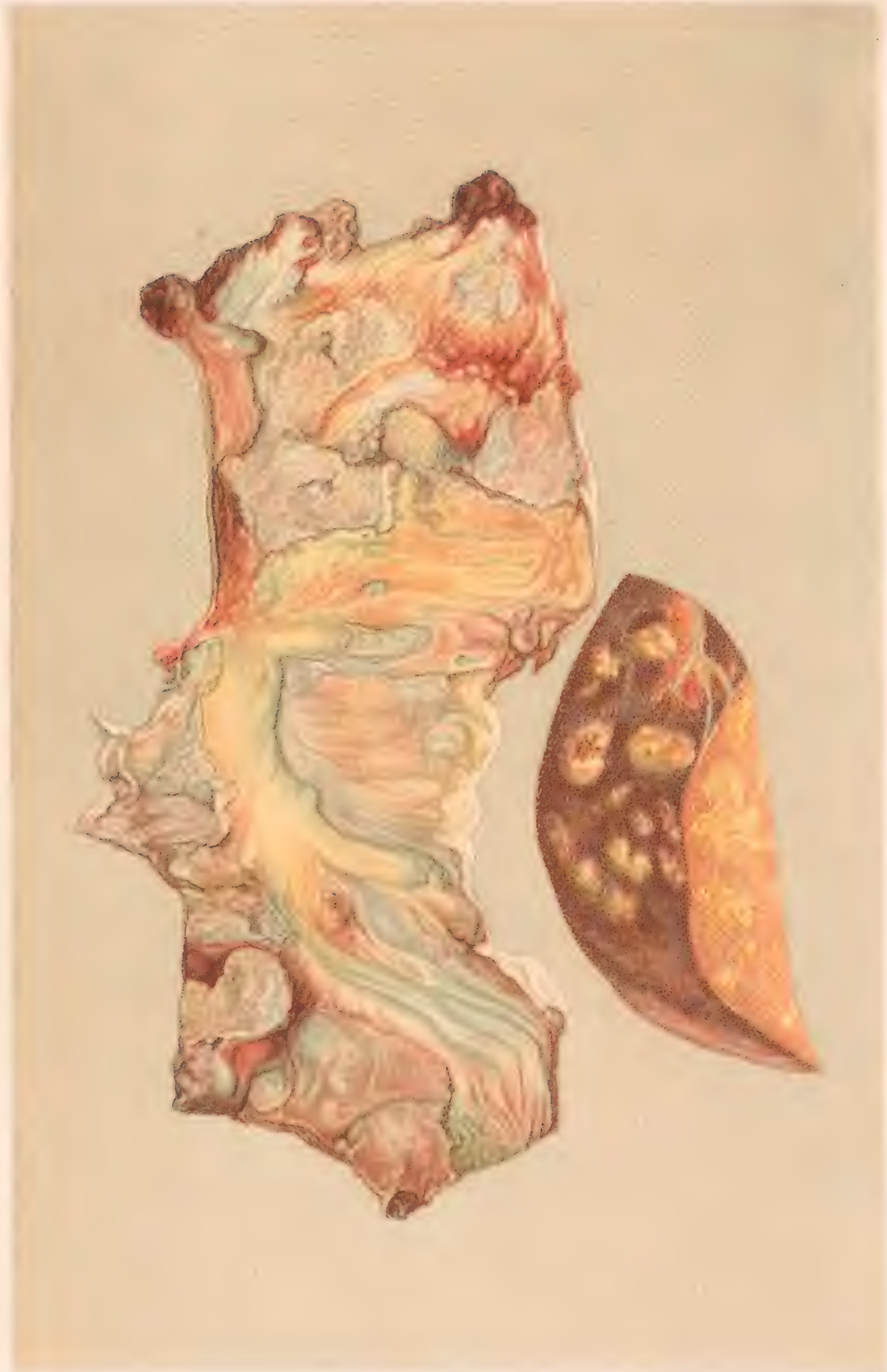
FIGURE 1. A. SECTION OF THE STEM OF A PLANT SHOWING THE  
CELLS OF THE CORK, X 100.



H. Faber pinxt.

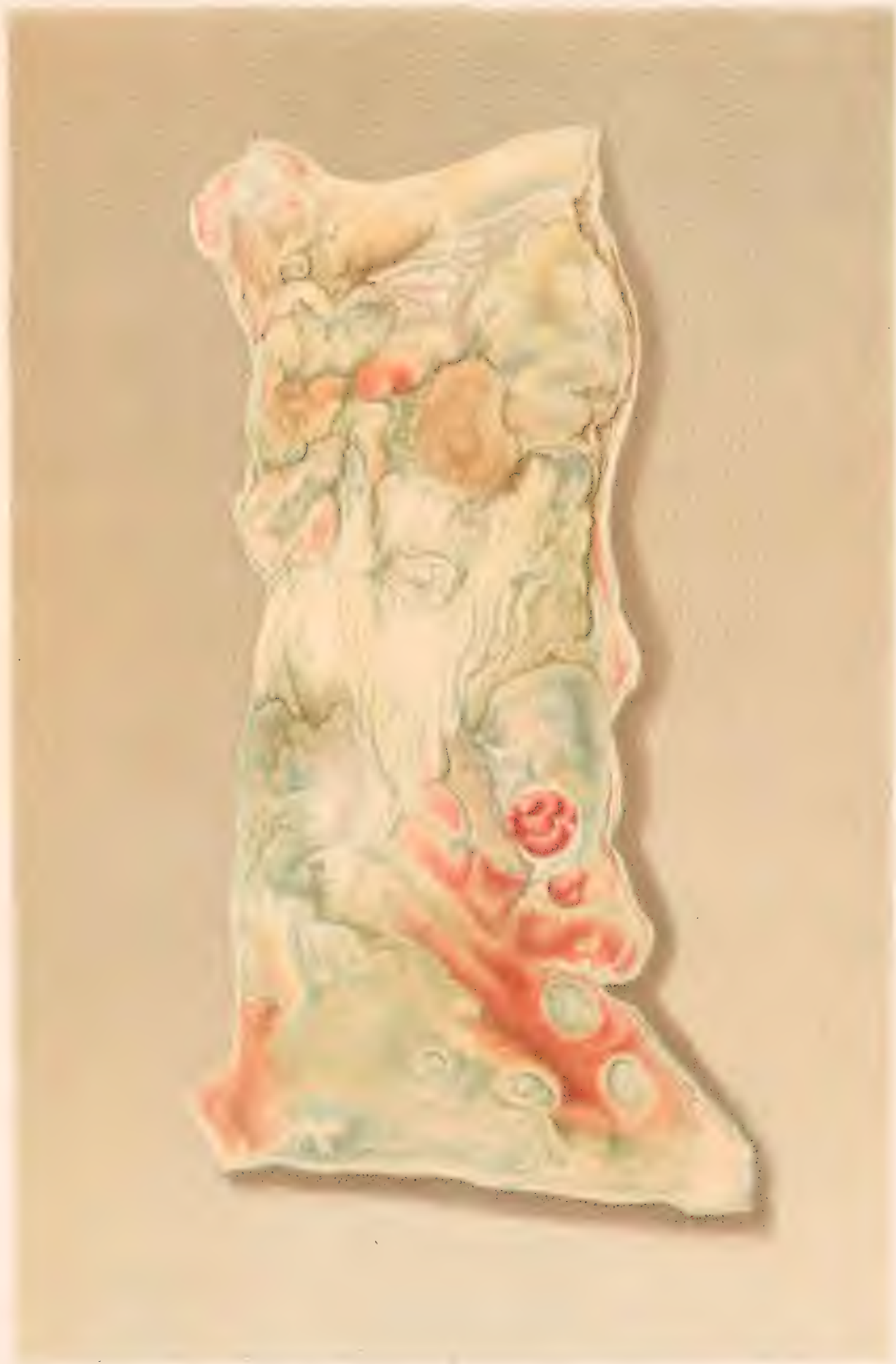F. Moras chromolith. Phila.

EXTENSIVE ULCERATION OF COLON.-CHRONIC DYSENTERY.  
GALLBLADDER FILLED WITH LITHES.









ULCERATION OF THE COLON.

No. 5. Medical Section







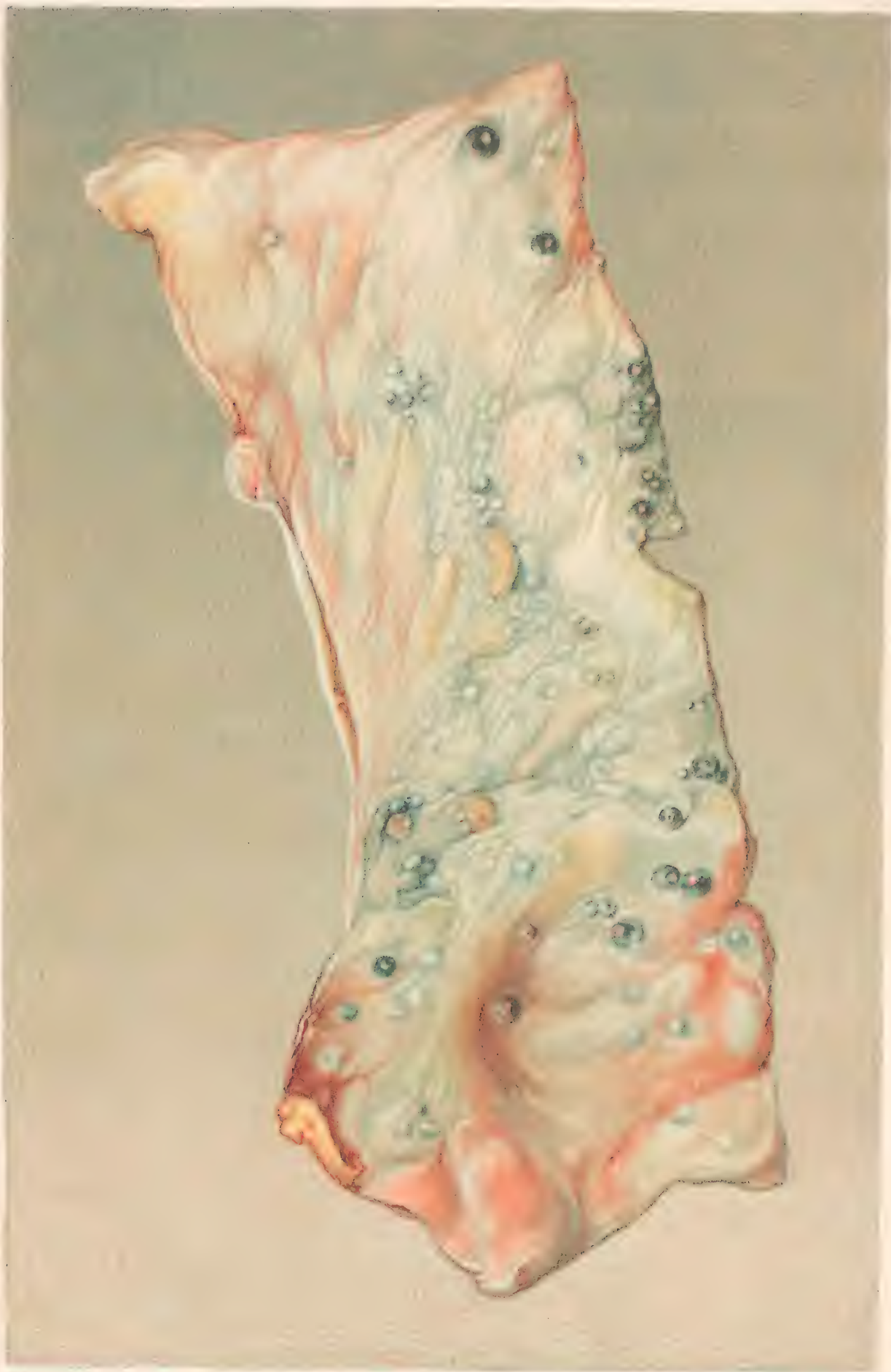
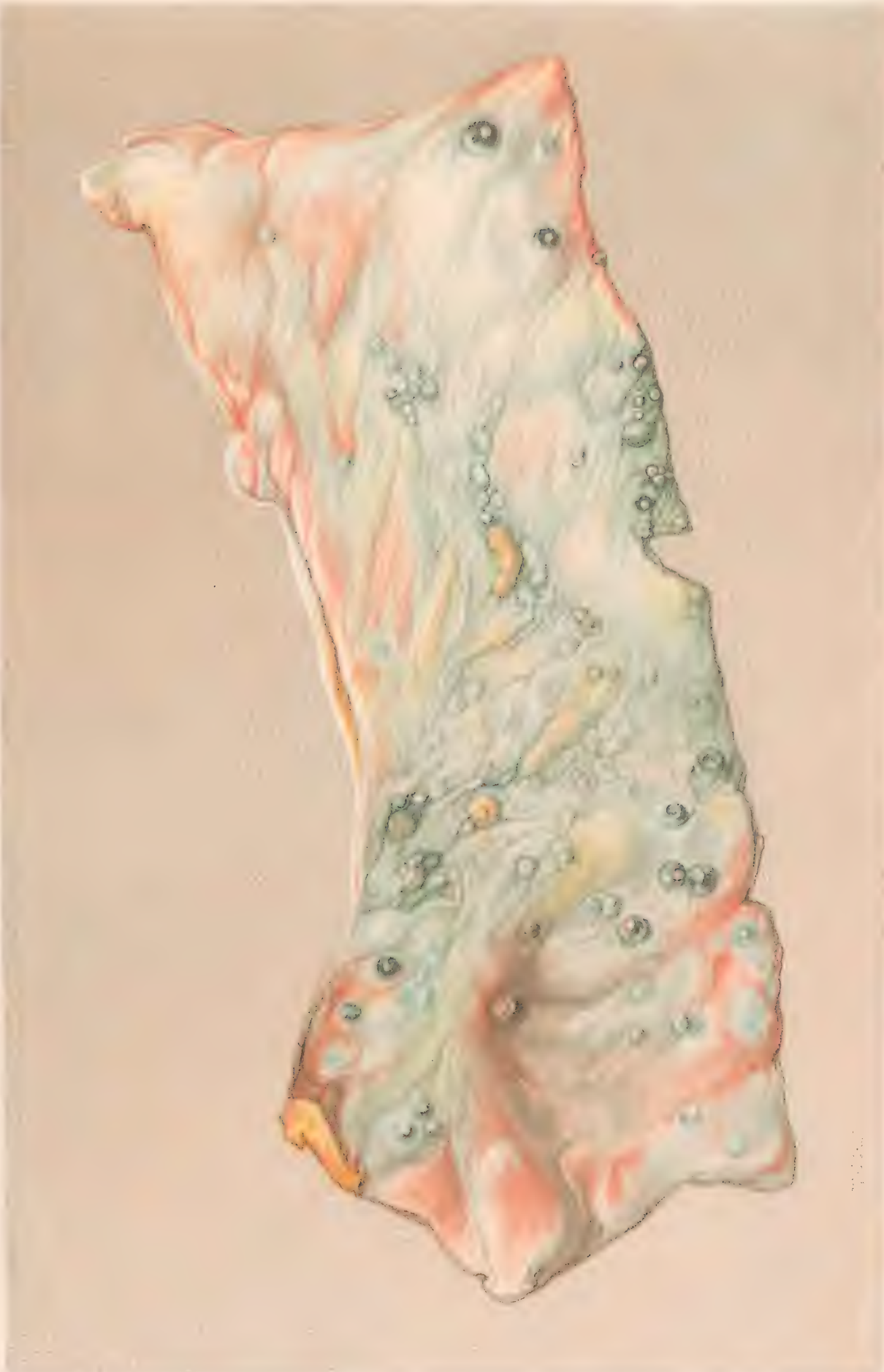
FIGURE 1. HEAD AND NECK OF A FISH.



R Faber pinx!

F Moras chromolithi Phila

COLON IN THE STATE OF HEALTH - COLIC AND DYSSENTERY.







PLATE I. A. B. C. D. E. F. G. H. I. J. K. L. M. N. O. P. Q. R. S. T. U. V. W. X. Y. Z.

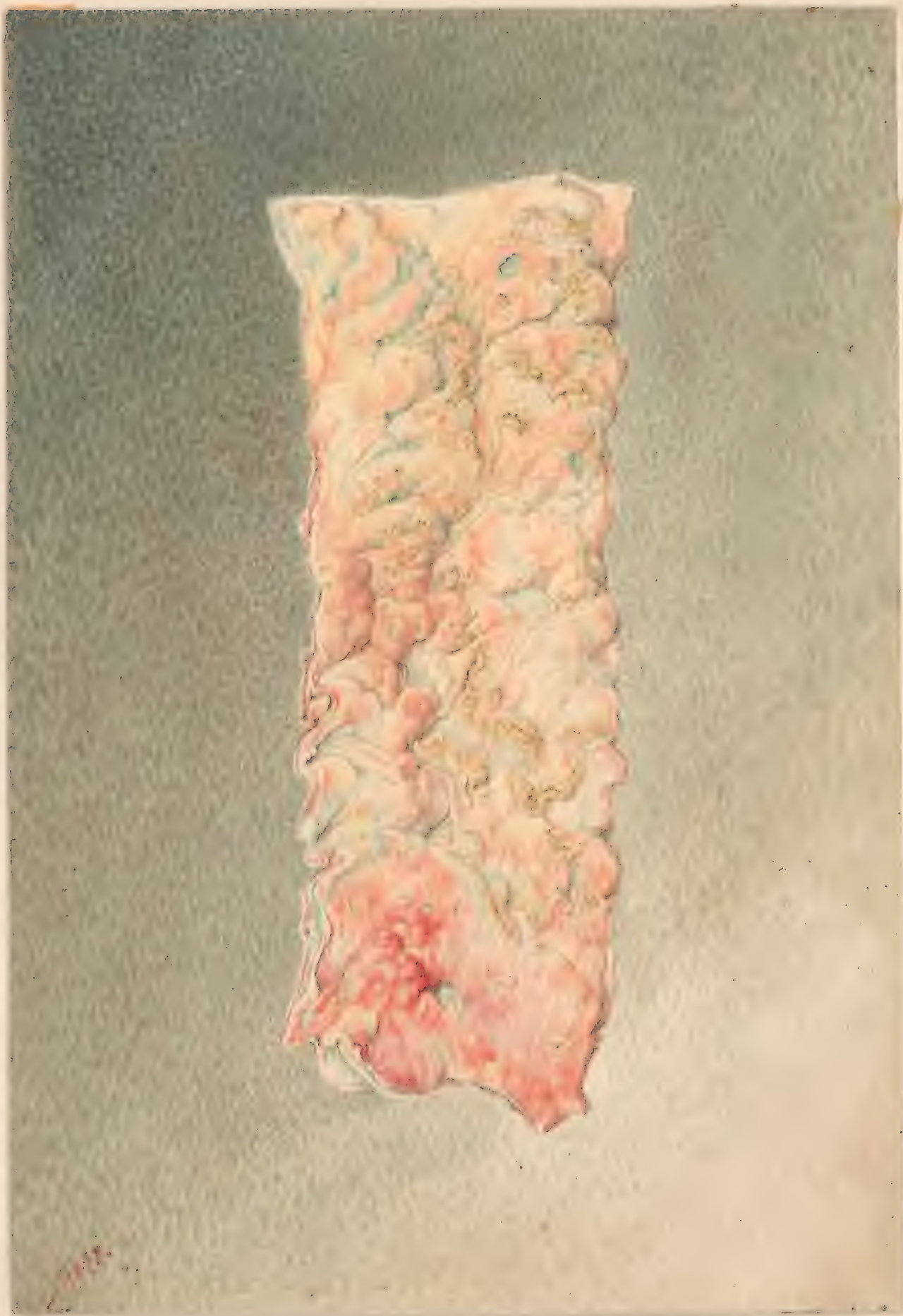The color is thickened and anæmic

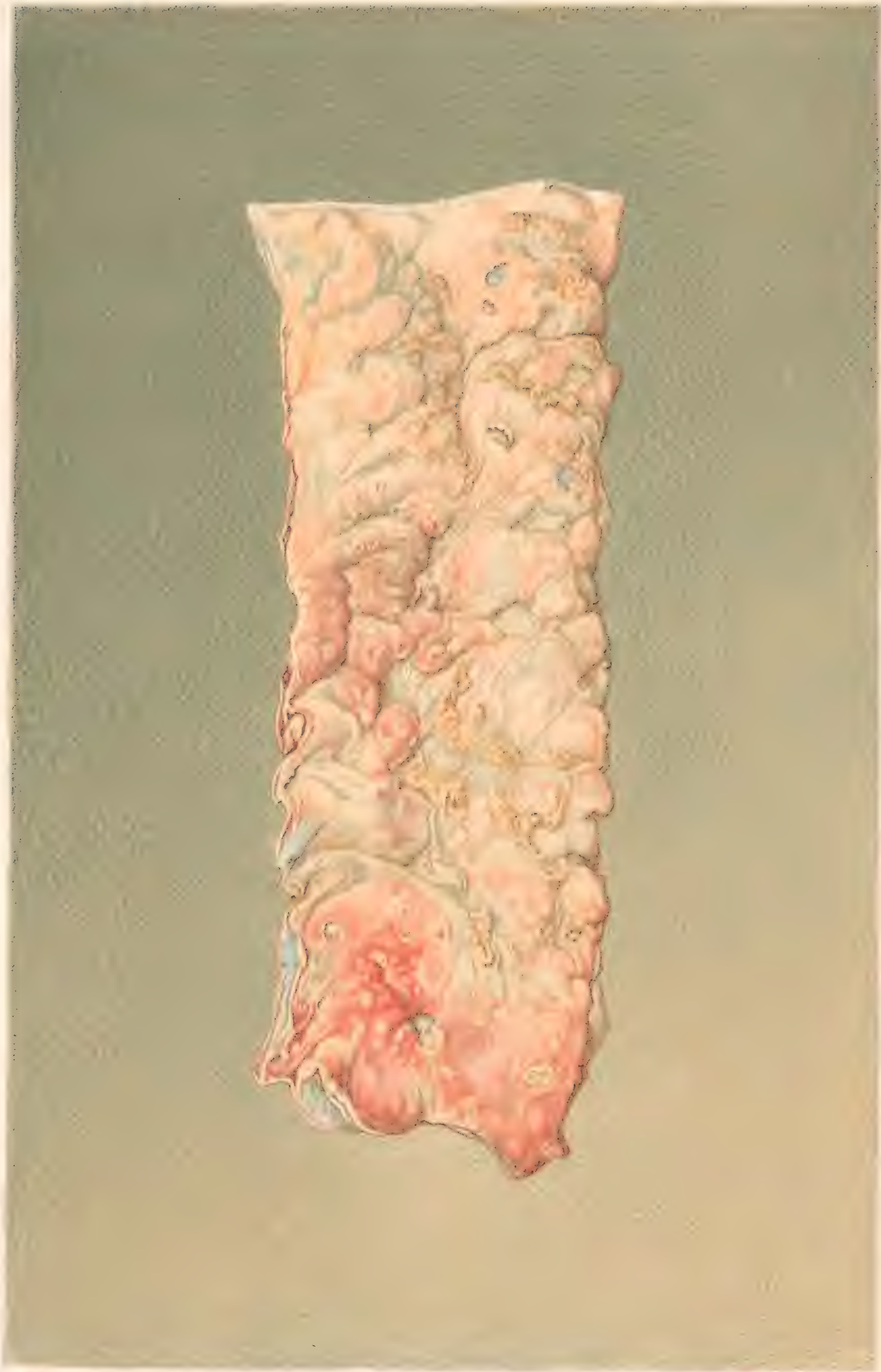

Fragment of a document, possibly a letter or a page from a book, showing faint red markings or text.



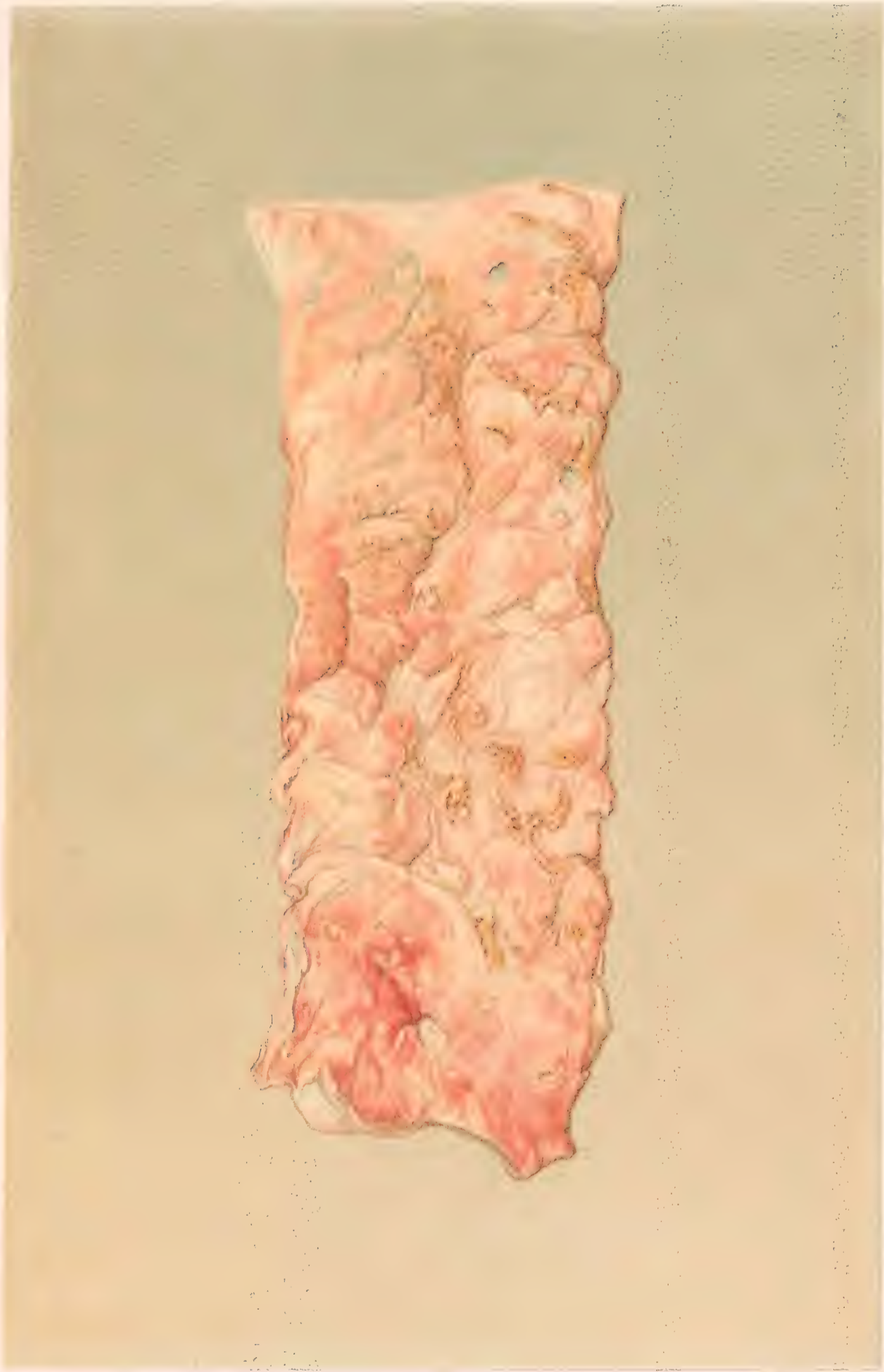






ΕΥΛΕΙΜΜΑΤΑ ΜΕΤΕΦΕΡΙΣΤΑΛΩΣ, ΟΥΛΕΡΑΙΣ Ω ΤΩΘΕΡΕΩΤ.

The edges of many of the ulcers are fringed with pseudo-membrane.



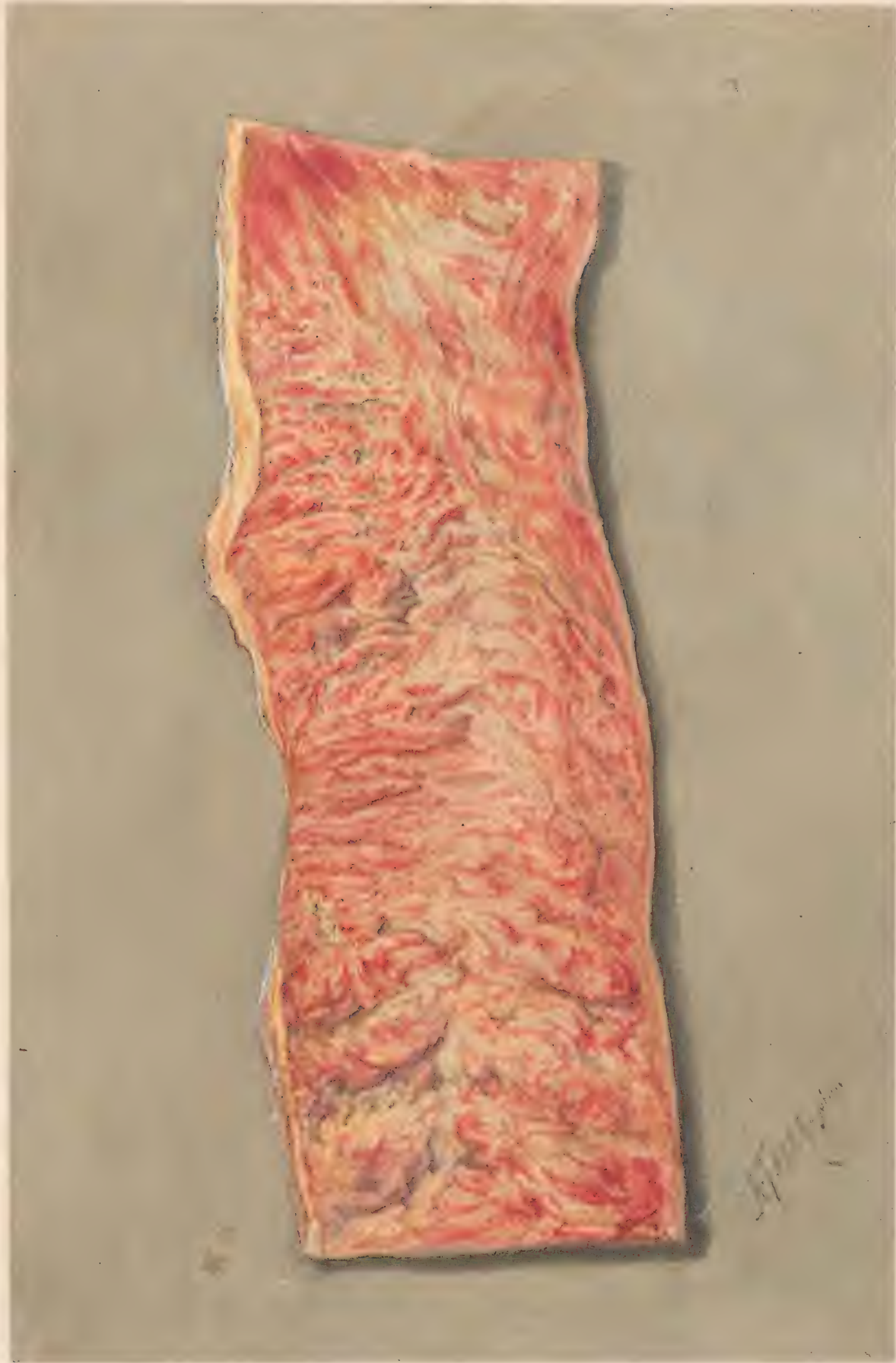H. Faber pinx.

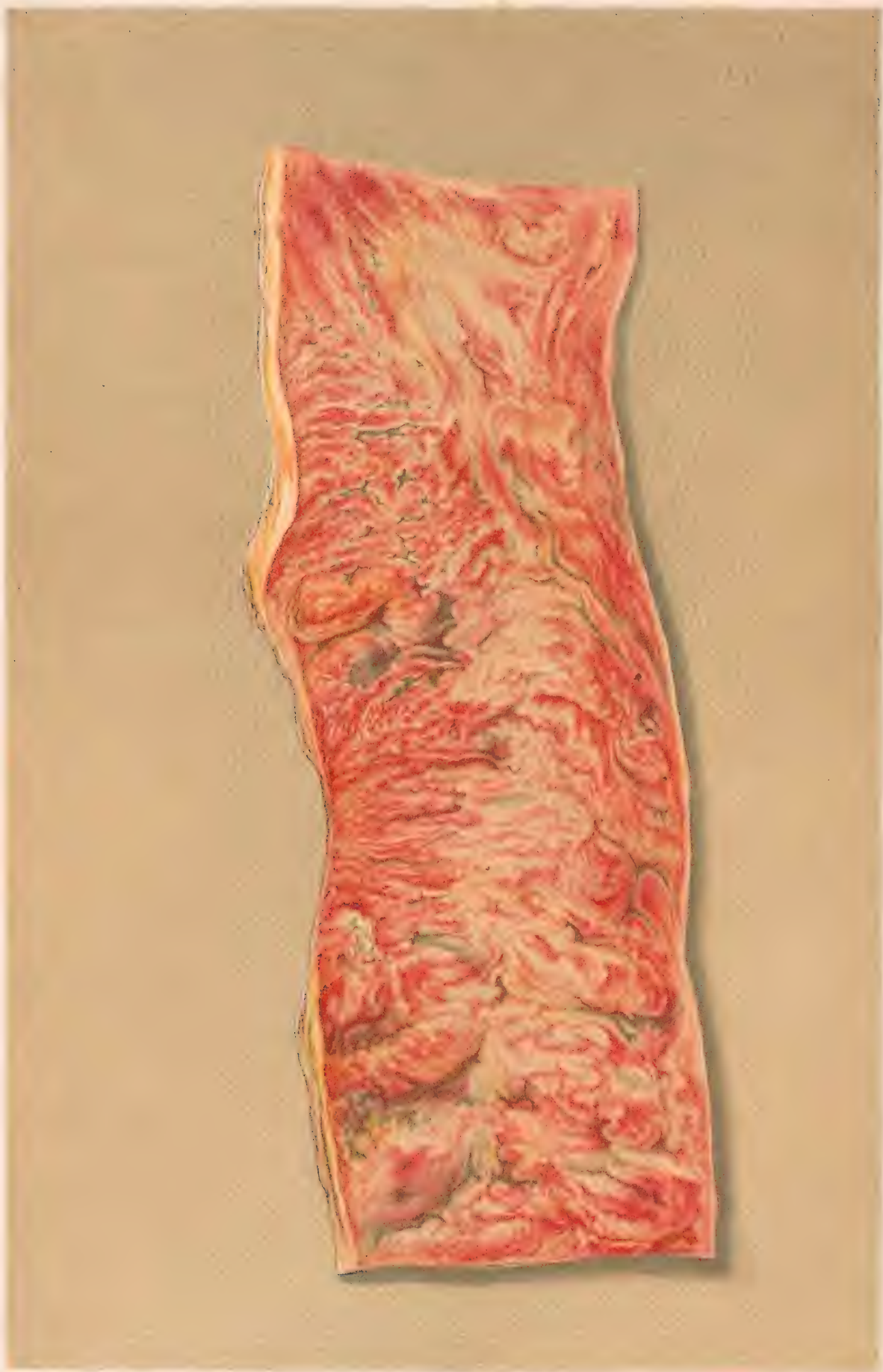F. Schmitt del.

**FOLLICULAR ULCERS OF COLON.-CHRONIC DYSENTERY.**

Edges of many of the ulcers are fringed with pseudomembrane.



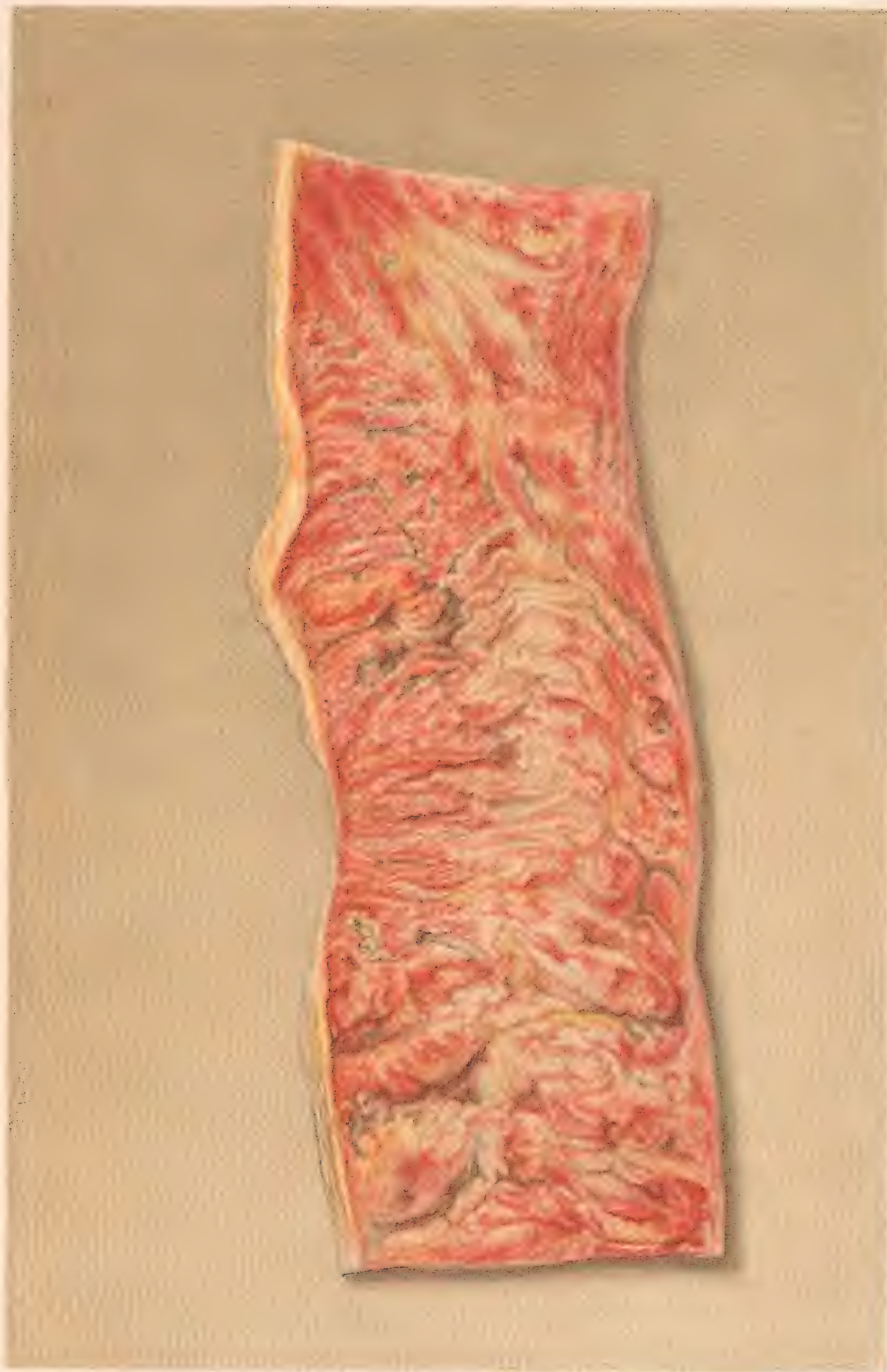




H. Faber pinx.

F. Martini chromolith. Phil.

PORTION OF DESCENDING COLON  
with patches of pseudo membrane, and small ulcers.



PORTION OF DESCENDING COLON  
with patches of pseudo-membrane and small ulcers





Originals

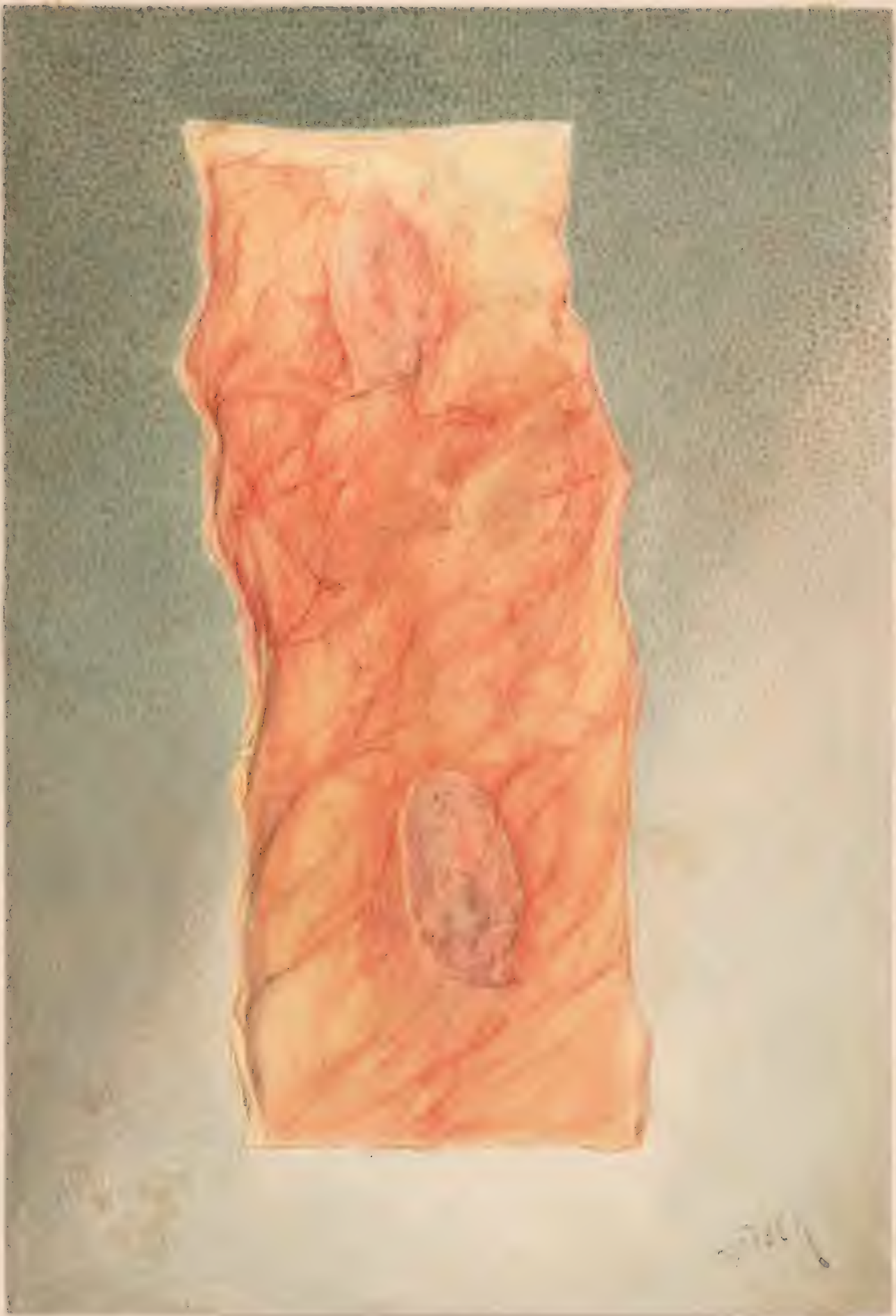
of the

in CHROMOS the

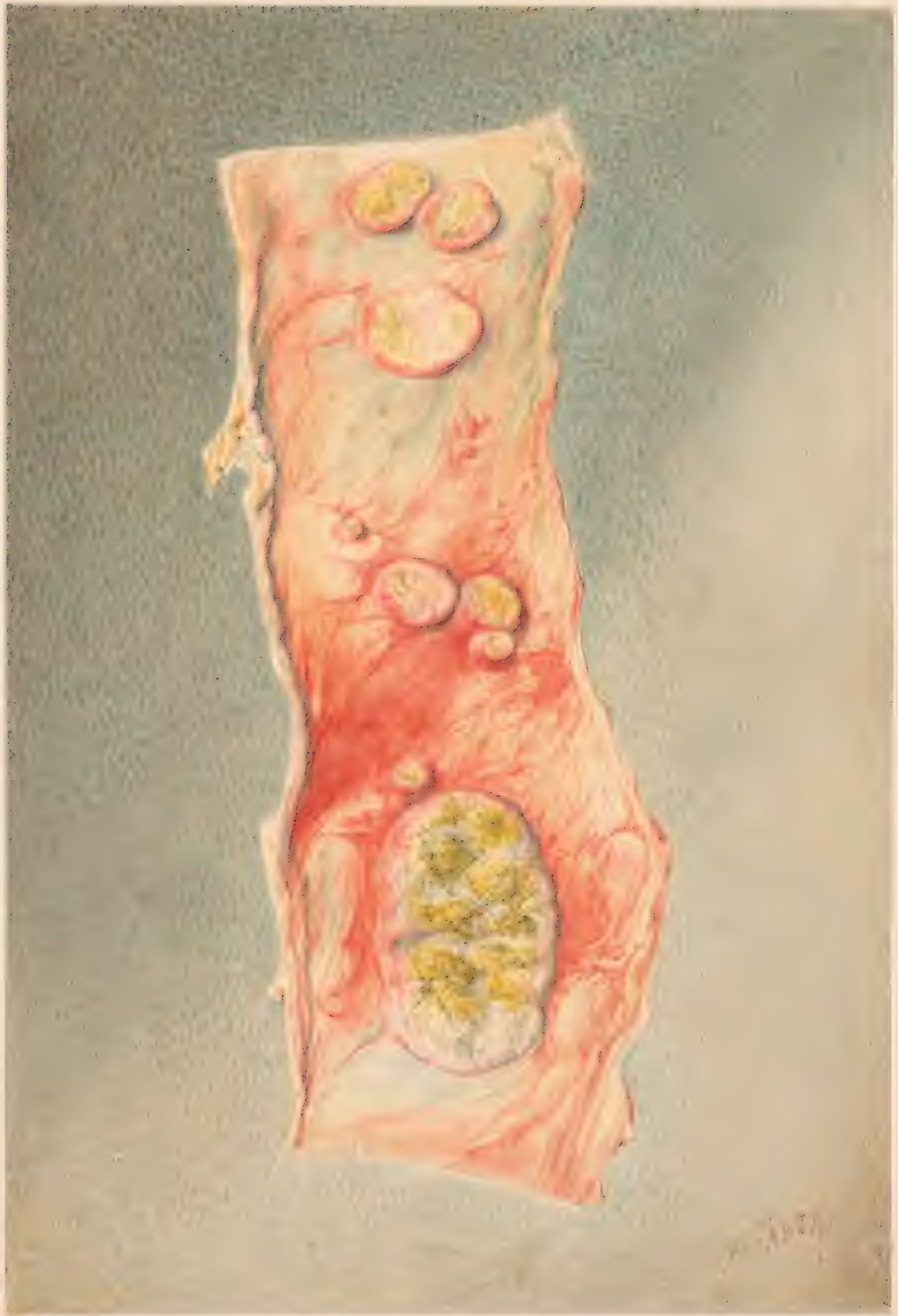
THIRD MEDICAL VOLUME.

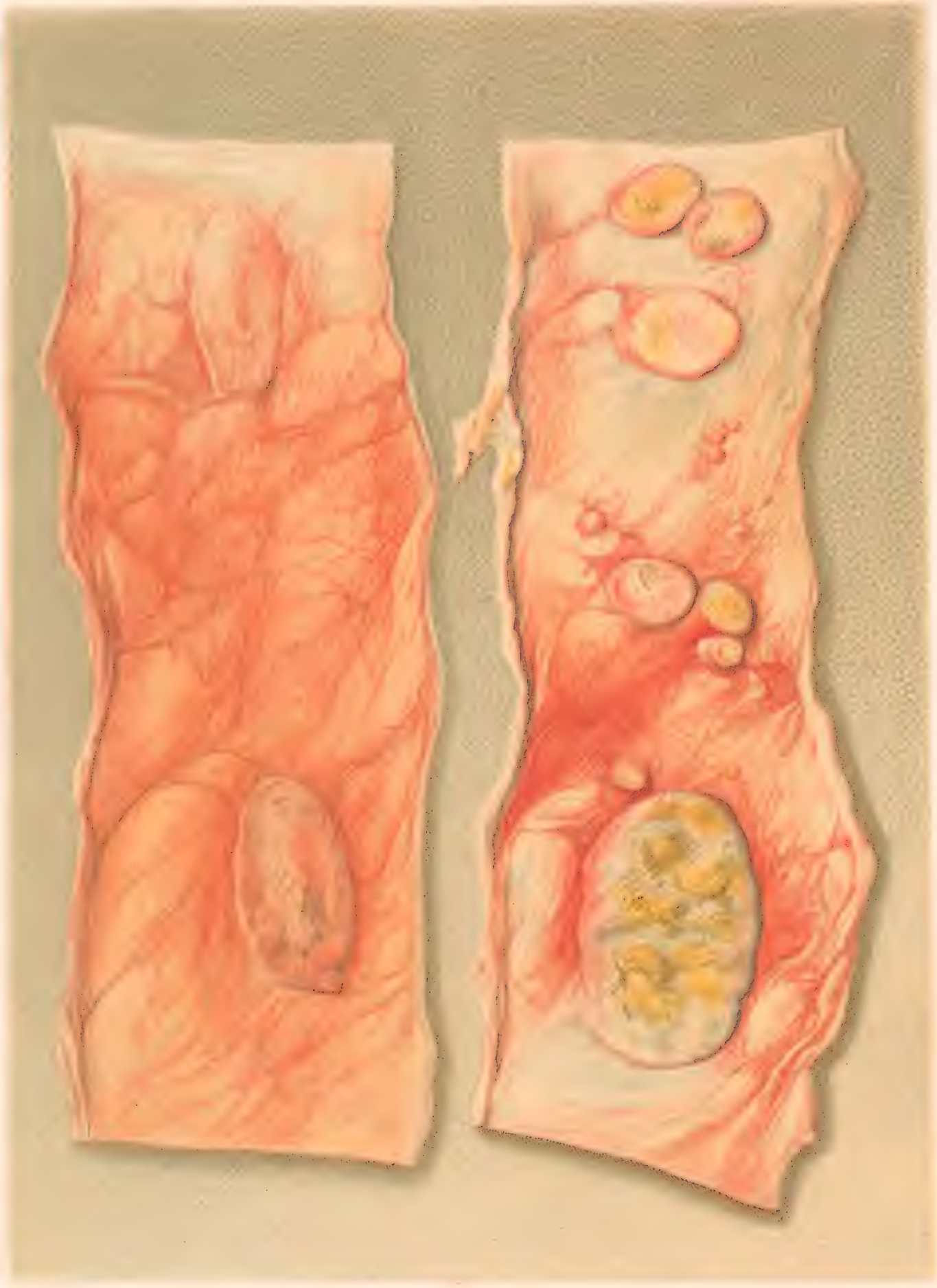
v. 1 pt 3

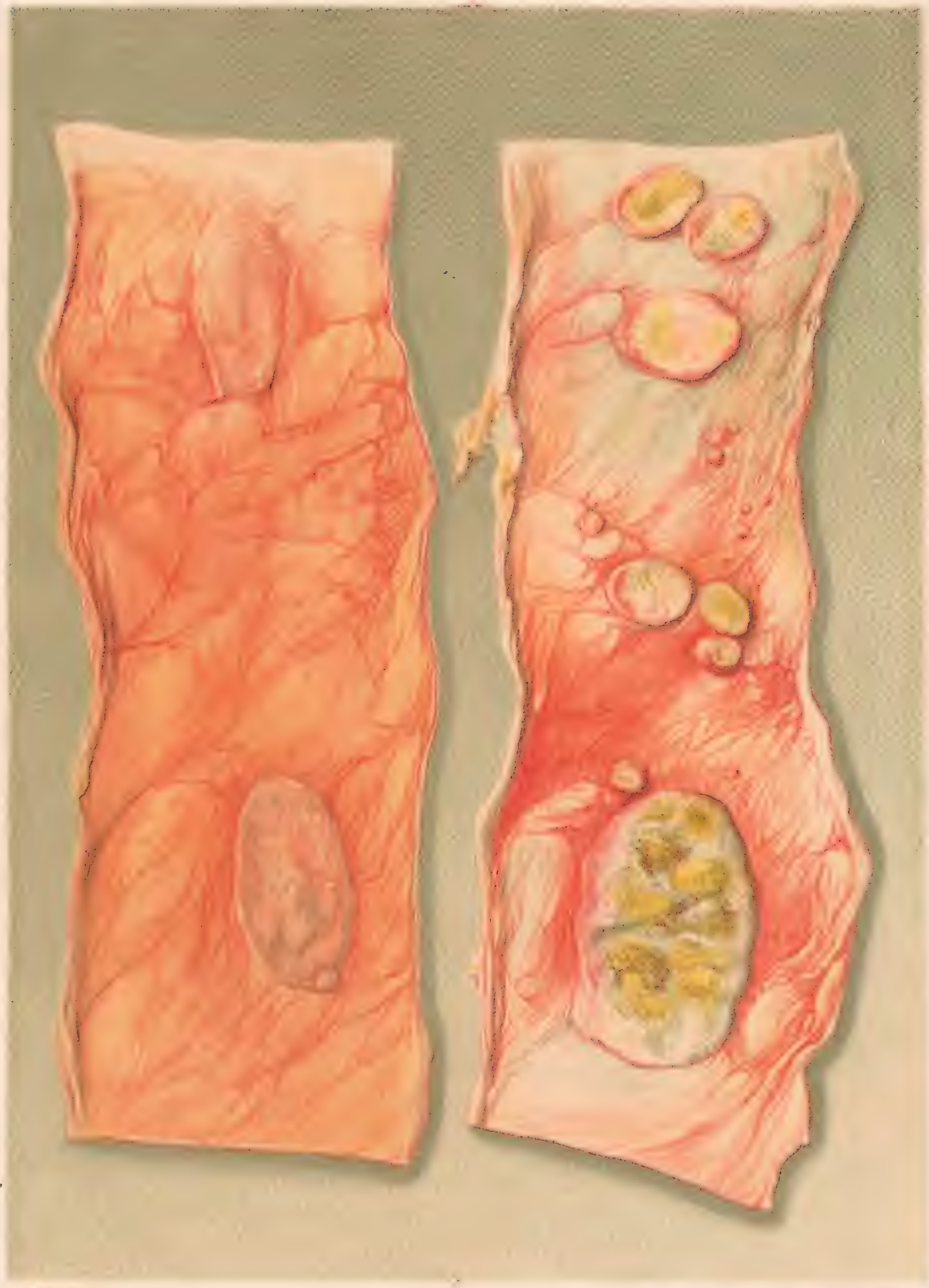








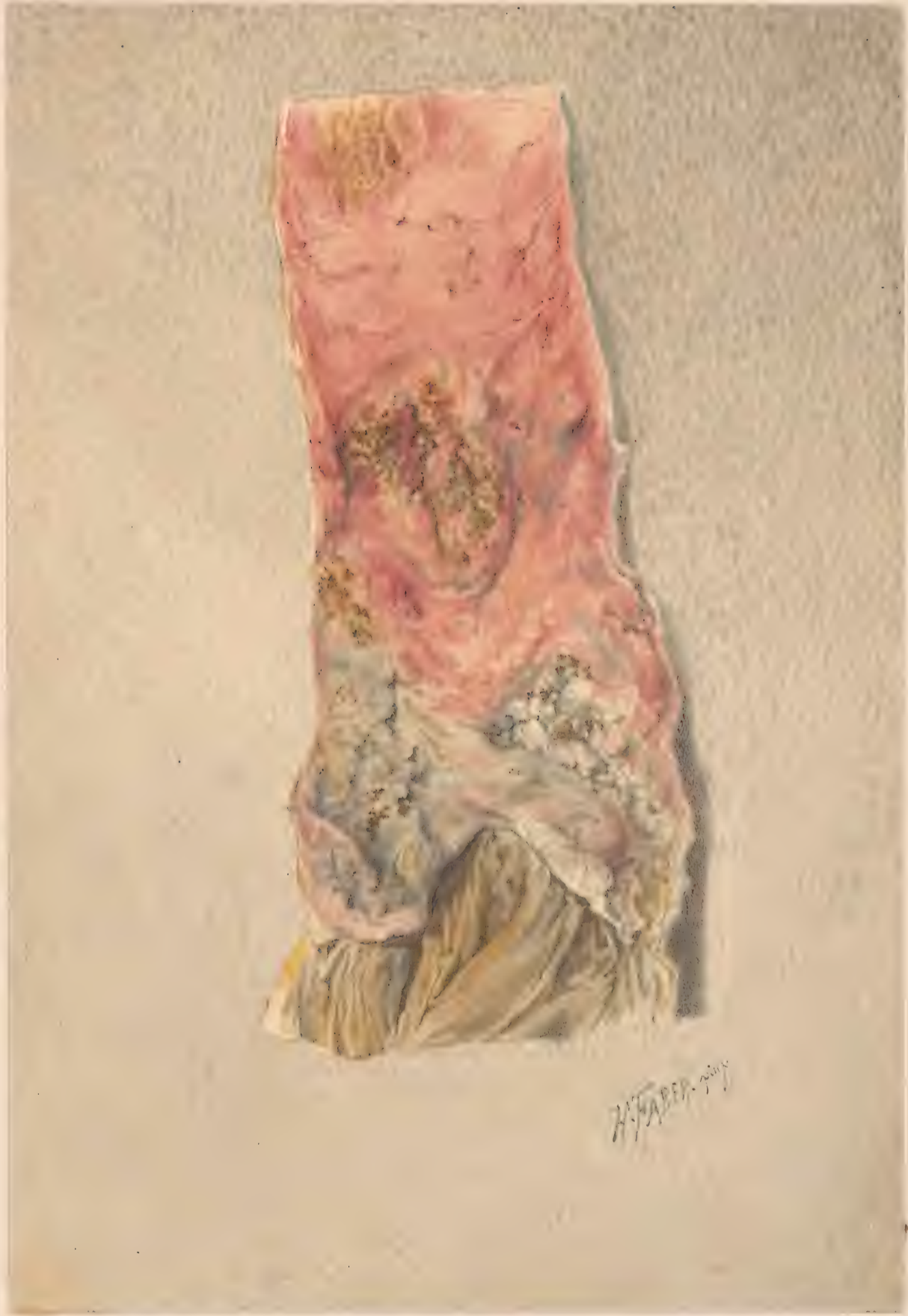


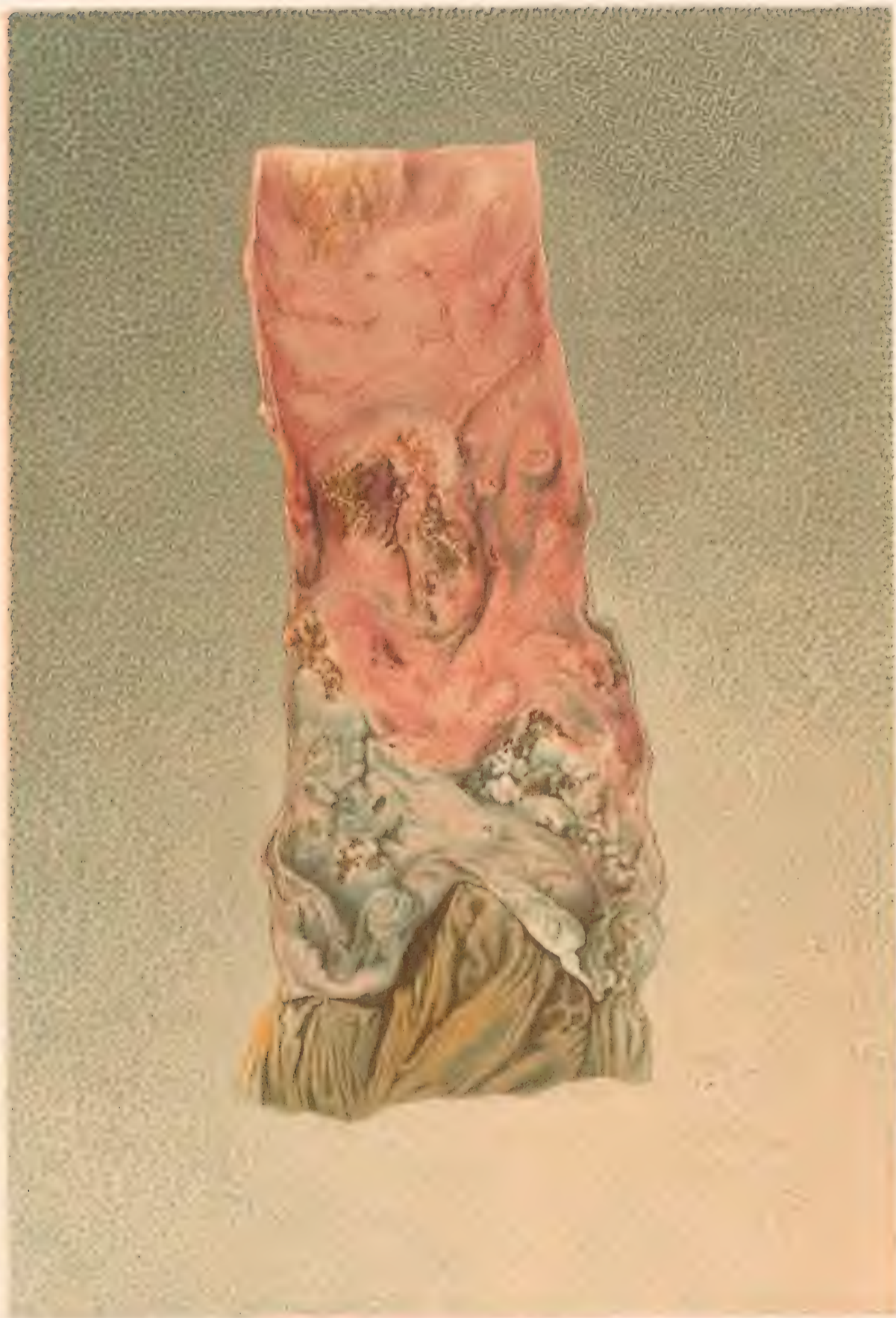
TYPHOID THICKENING OF PEYER'S PATCHES.









per dix

INCUBATED PESTER PLAGUE-FEVER,  
taken near the Neo-metal valve

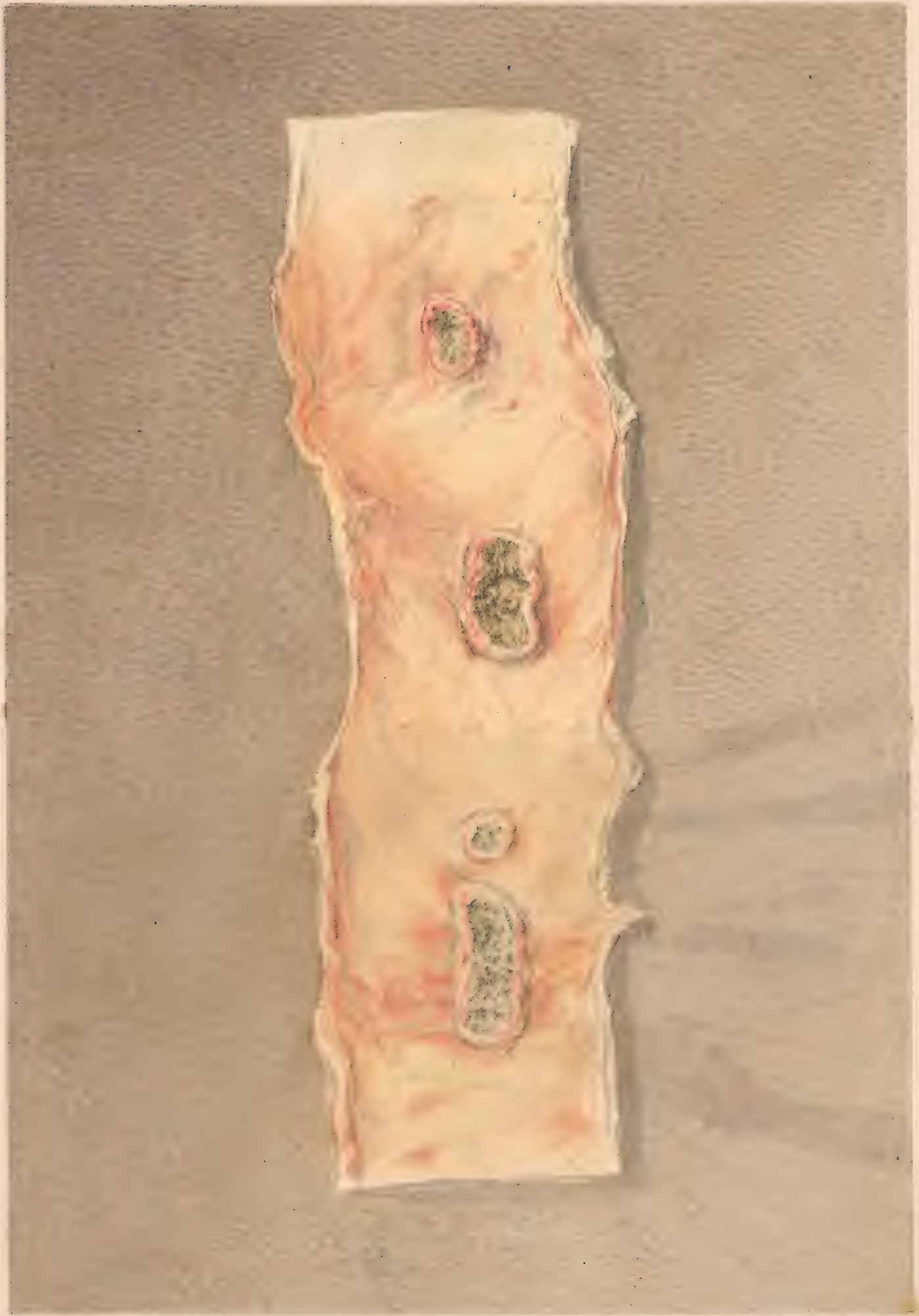
2 - 2114



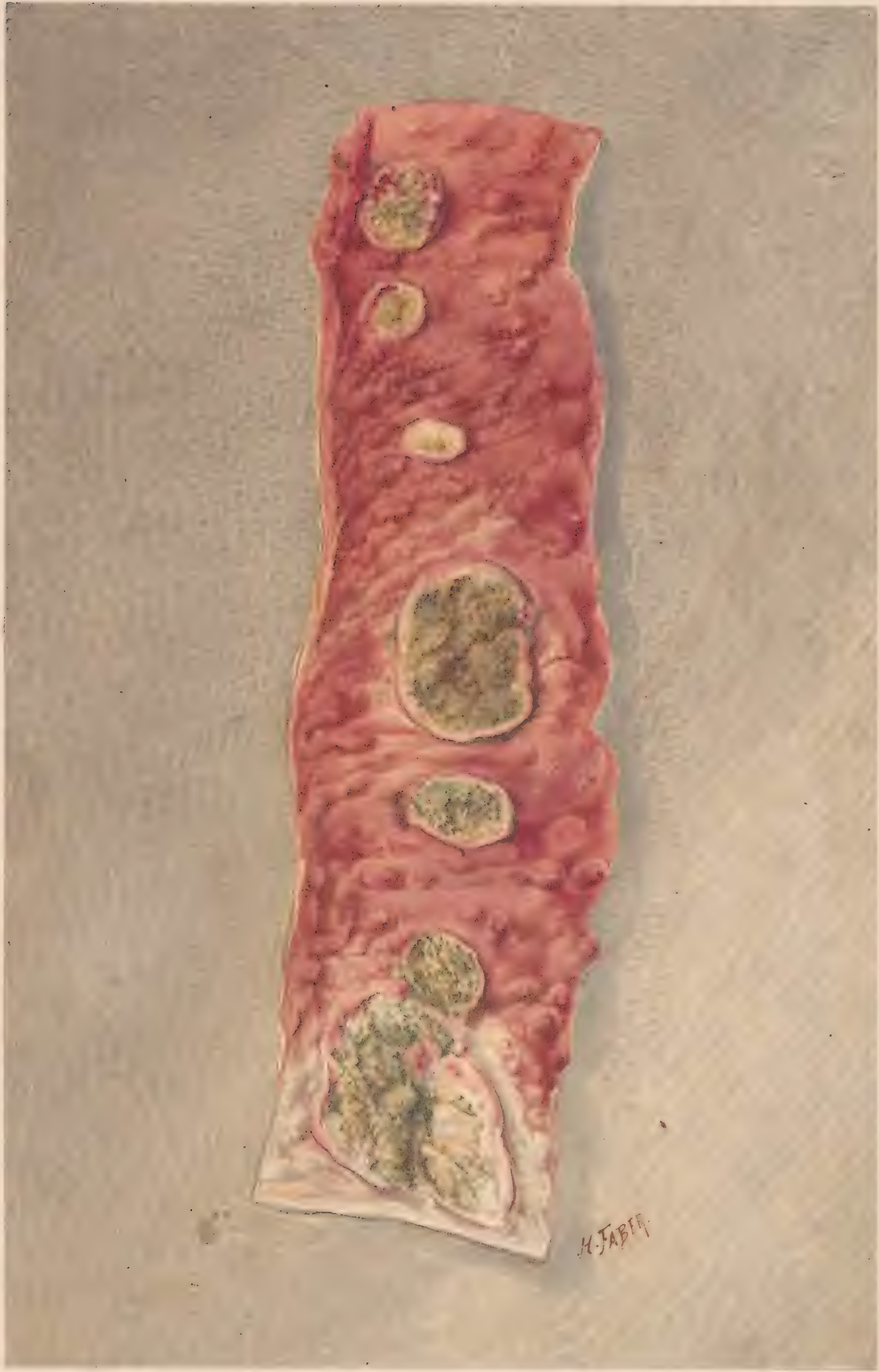Foras chrom. lit. Phil.

ULCERATED FEVER PATCH.- FEVER  
taken near the ileo-coecal valve.









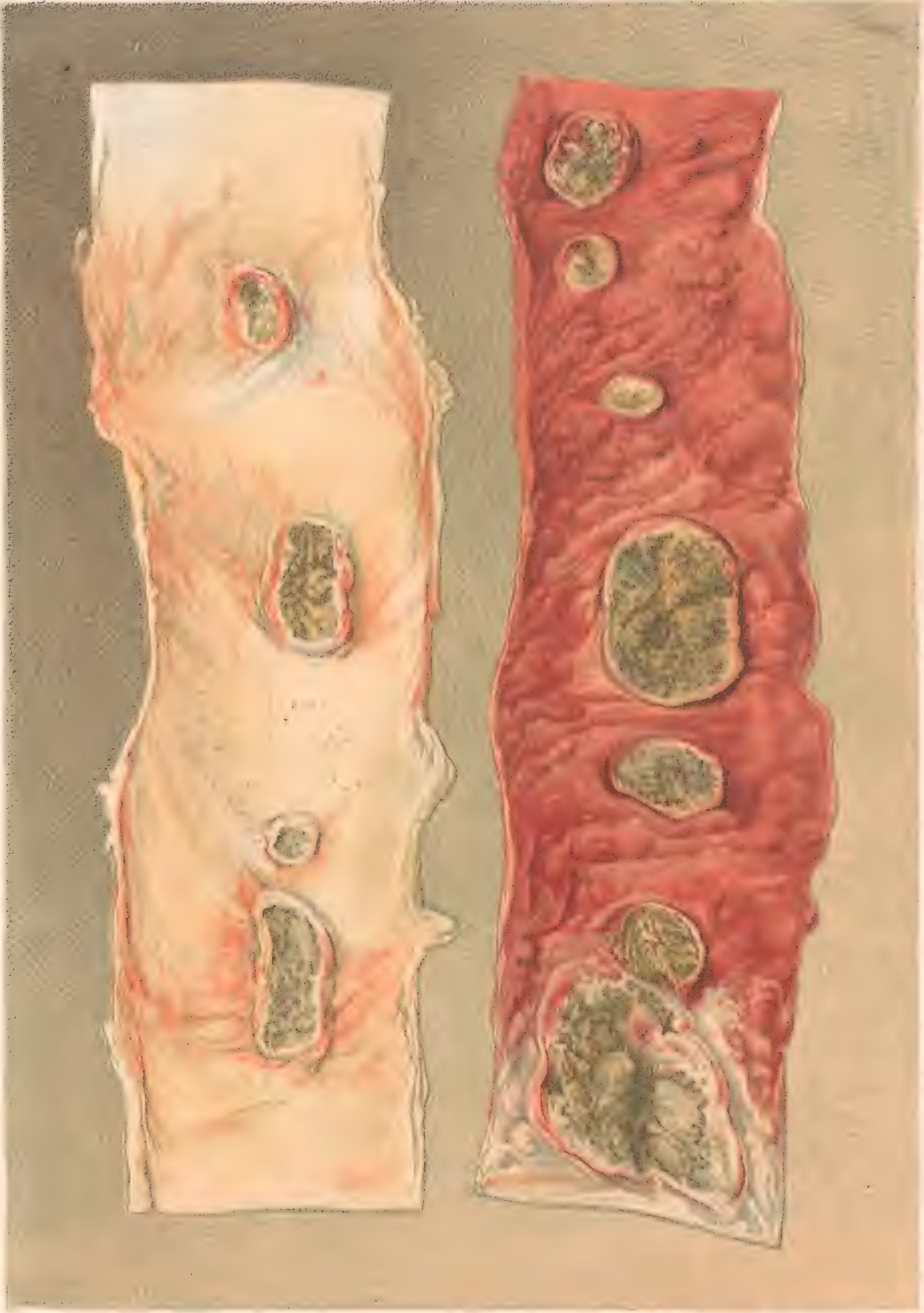


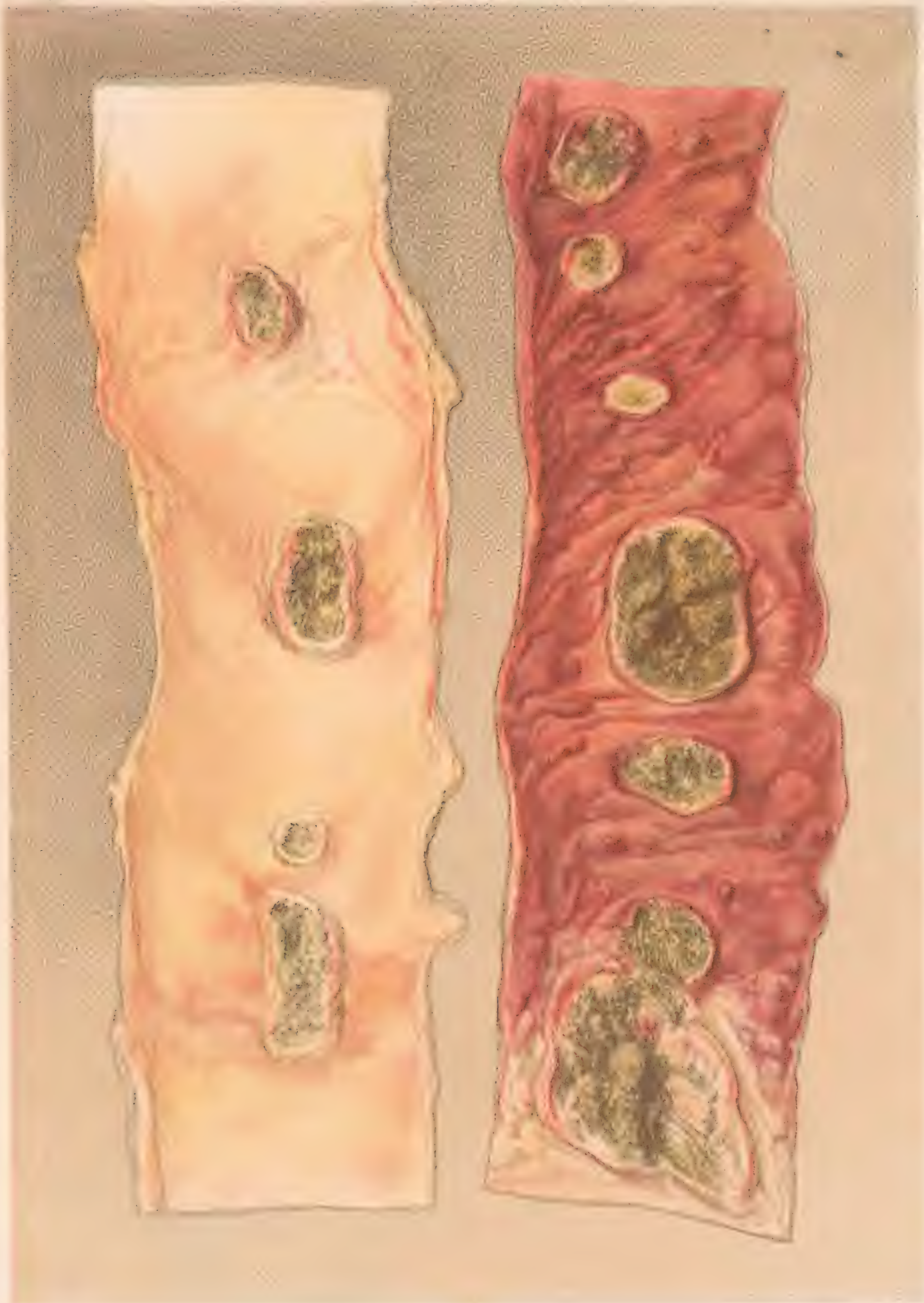
PLATE 100

F. Moras cromolith Philad.

THE LEFT PIECE FROM THE UPPER, THE RIGHT FROM THE LOWER PART OF THE ILEUM.



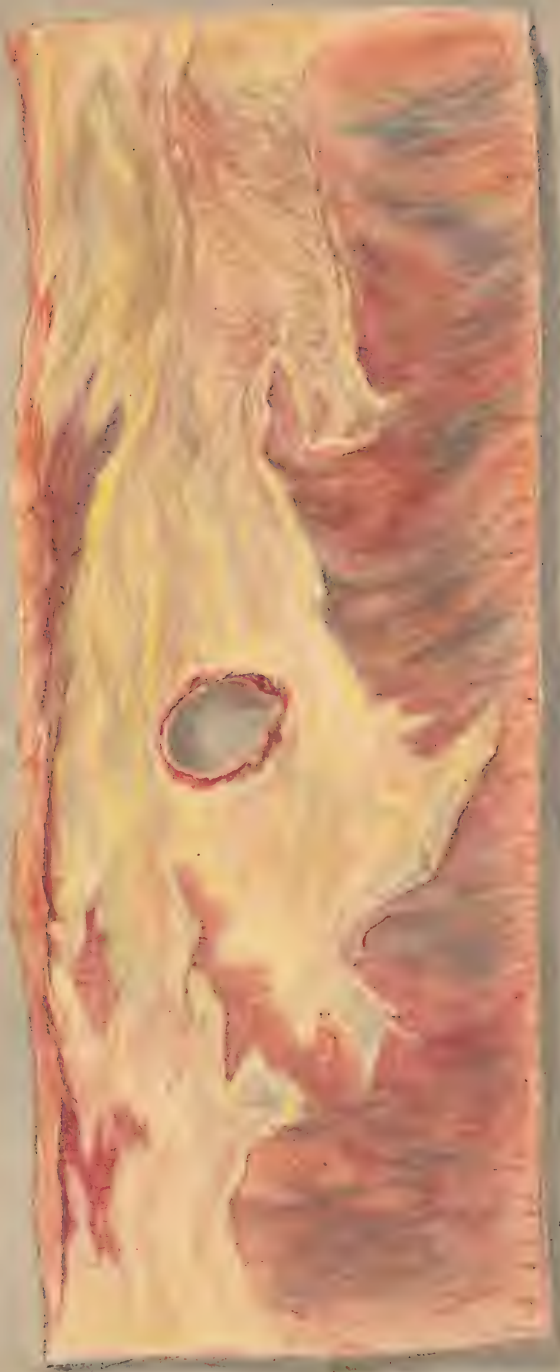
2" of wood maple



H. Faber. 1861.

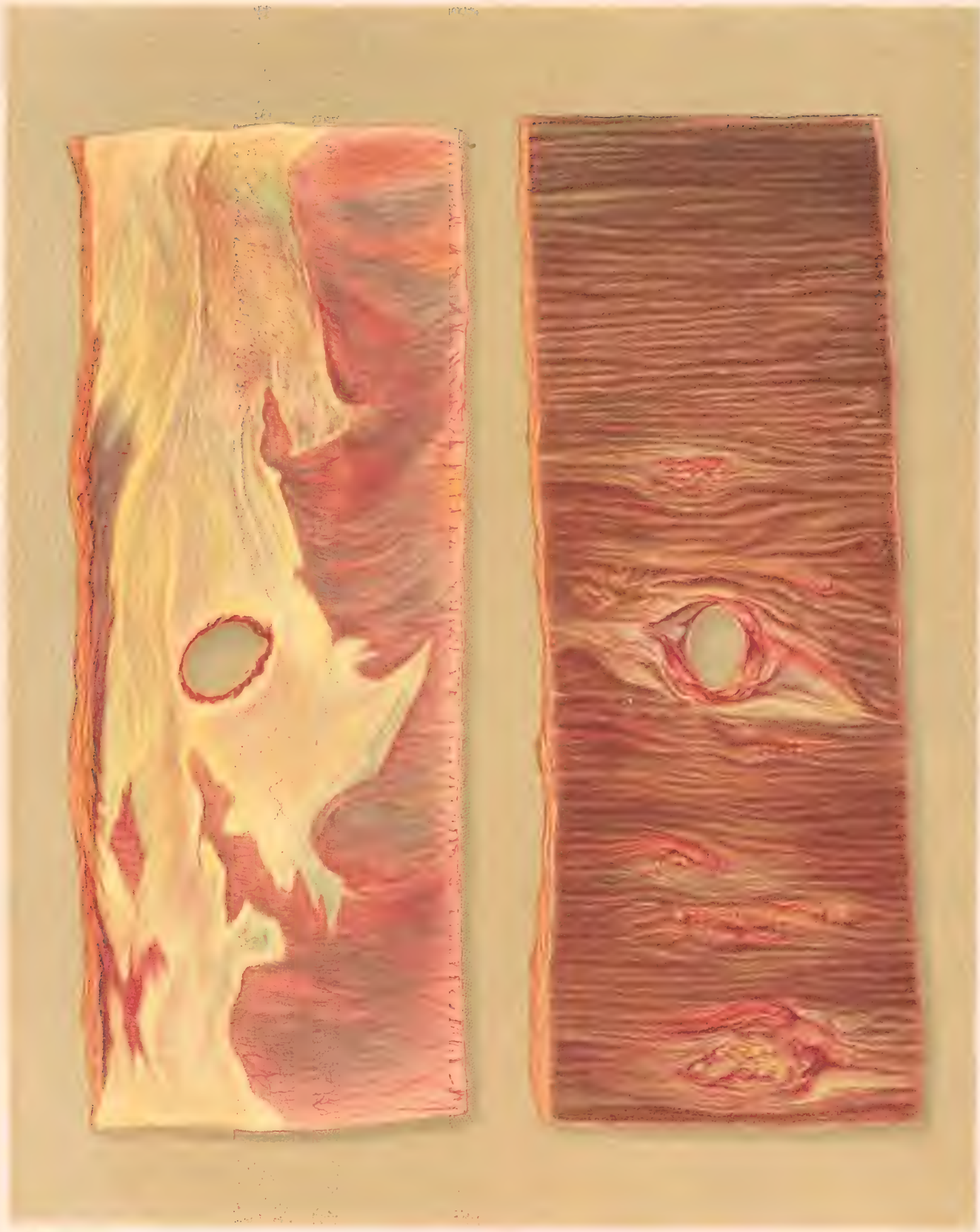WOODS OF THE UNITED STATES  
BY HENRY F. FORTY, U.S. GEOLOGICAL SURVEY





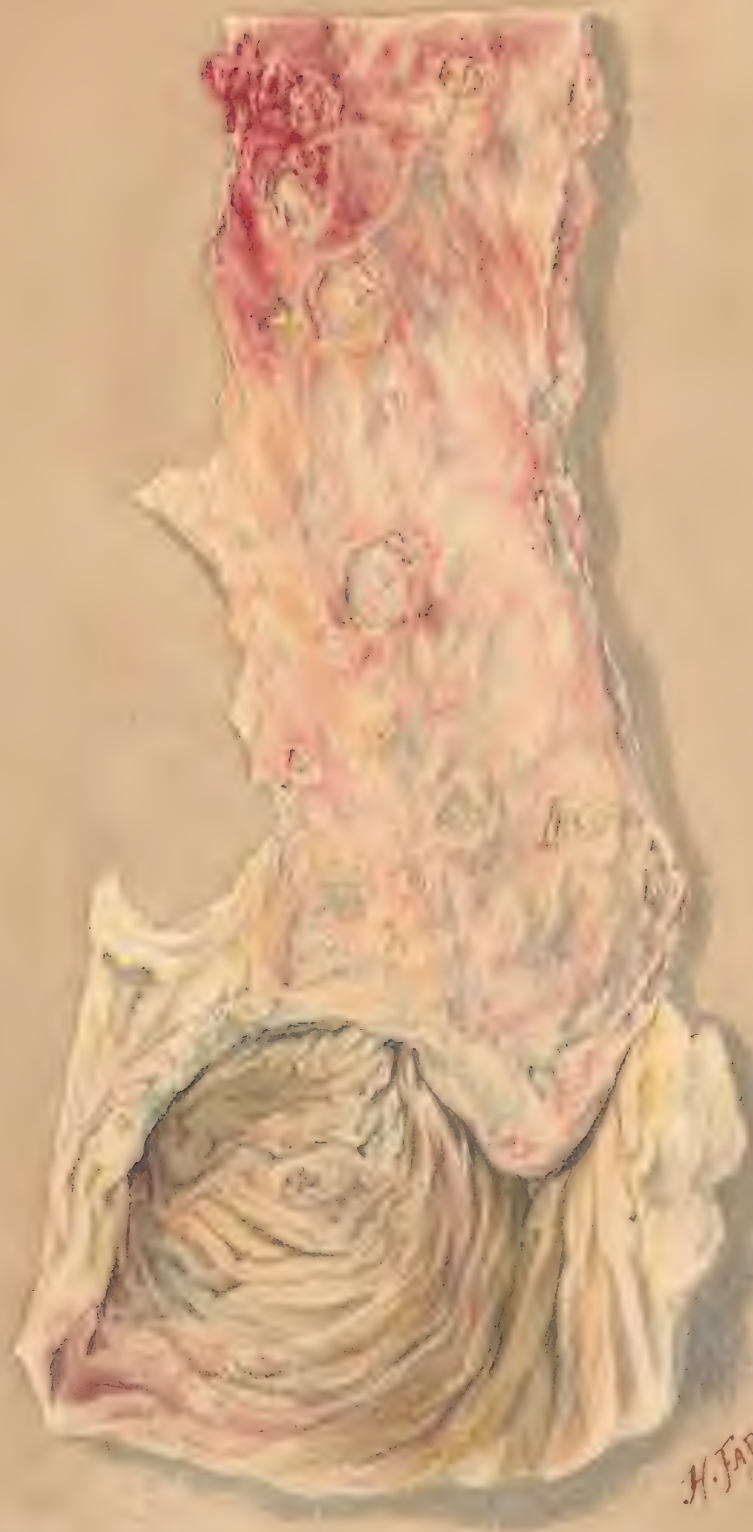10749





**PERFORATING ULCER OF THE ILEUM.**  
The right hand piece shows the mucous, the left the peritoneal surface.

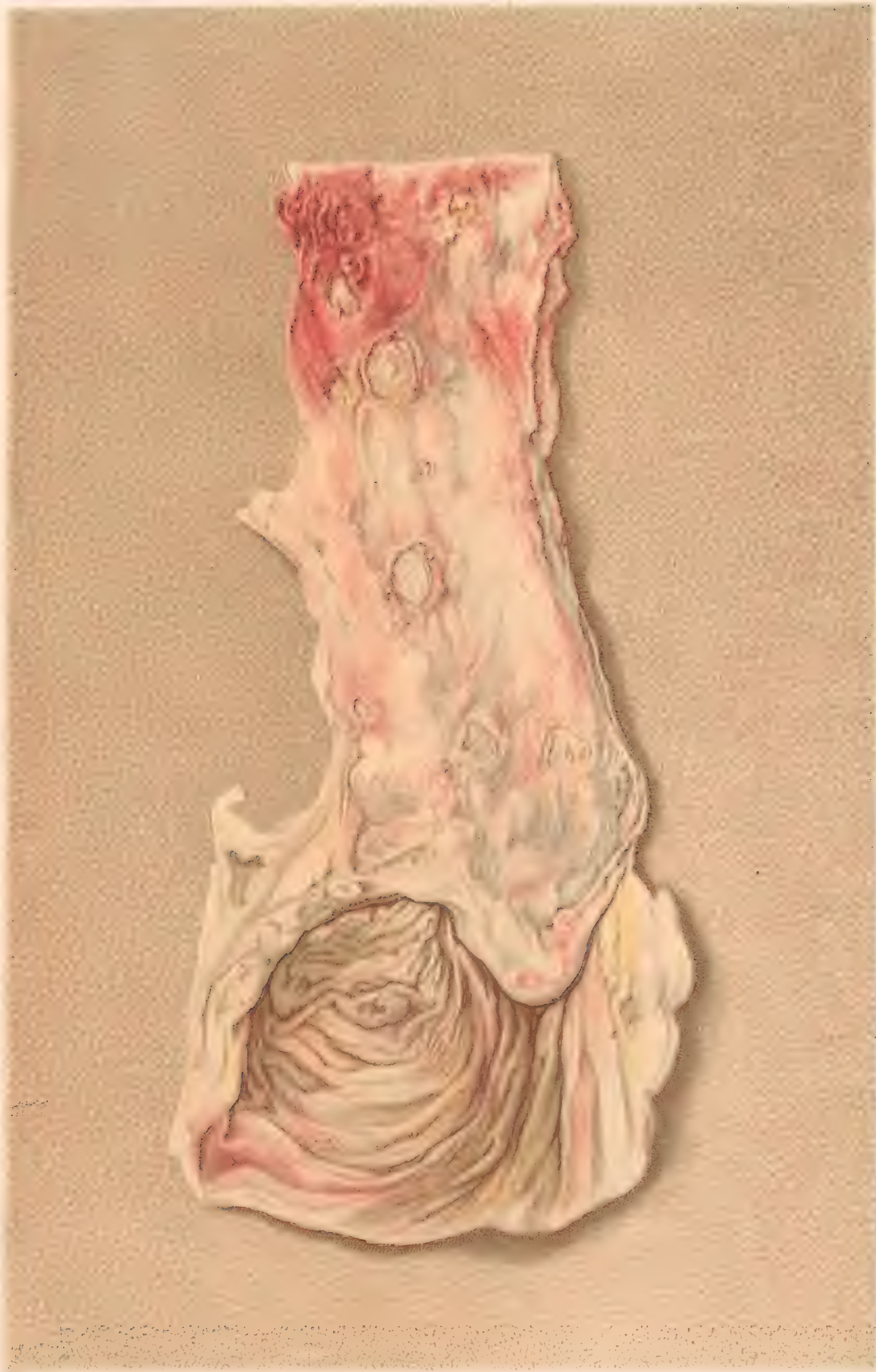



H. FARCH.  
17







ULCERATION OF THE ILEUM AND CAECUM





